



Radiographic alterations of the frontal sinus morphology according to variations of the vertical angle in posteroanterior radiographs of the skull

Rhonan Ferreira Silva¹, Camilla Galvão Vaz¹, Mariana Leão Domiciano¹, Ademir Franco^{2*}, Carla Aparecida Bernardes da Costa Meneses Nunes¹ and Mauro Machado do Prado¹

¹Universidade Federal de Goiás, Goiânia, Goiás, Brazil. ²Forensic Odontology, Department of Oral Health Sciences, Katholieke Universiteit Leuven, Leuven, Belgium. *Author for correspondence. E-mail: franco.gat@gmail.com

ABSTRACT. The frontal sinuses play a highly relevant role in comparative human identification processes. Since forensic radiology is a branch in the forensic sciences, adequate radiological analysis of the frontal sinuses is essential for comparative human identifications. The current study investigates radiographic morphological changes in the frontal sinuses according to vertical angle distortions in posteroanterior (PA) radiographs. A standard PA radiograph of the skull of an adult was obtained. Eight addition PA radiographs were taken at different vertical angles. Frontal sinuses were analyzed qualitatively and quantitatively according to Ribeiro's (2000) technique. Both qualitative and quantitative analyses revealed significant image distortions. Further, overlapping anatomical structures were reported when PA radiographs were analyzed in negative angulation distortions (from -10° to -40°). Positive and negative angular distortions up to 20° slightly affected the qualitative morphological analysis. However, 10° positive and negative distortions provided a significant interference in quantitative analysis and impaired the measuring process. Most forensic techniques for the analysis of frontal sinuses comprise measurements of morphological distances. Distortions of approximately 10° or over in vertical angulation of cranial PA radiographs should be avoided so that more accurate comparative human identifications could be achieved.

Keywords: frontal sinus, radiographic technique, forensic anthropology, human identification.

Alterações radiográficas da morfologia dos seios frontais variando o ângulo vertical em radiografias pósterio-anteriores

RESUMO. Os seios frontais desempenham importante papel no processo de identificação humana comparativa. Considerando a radiologia forense como área adjacente às ciências forenses, tem-se na análise radiográfica dos seios frontais uma ferramenta essencial para identificações humanas comparativas. O presente estudo visa investigar as alterações morfológicas radiográficas dos seios frontais variando o ângulo vertical em radiografias pósterio-anteriores (PA). Uma radiografia PA padrão foi obtida de um crânio adulto. Oito radiografias PA adicionais foram realizadas modificando-se o ângulo vertical. Os seios frontais foram analisados qualitativamente, e quantitativamente, por meio da técnica de Ribeiro, (2000). Ambas as análises revelaram distorções imaginológicas significantes. Além disso, a sobreposição de estruturas anatômicas foi observada quando analisadas radiografias PA com distorção angular negativa (de -10° a -40°). Distorções angulares positivas e negativas de até 20° pouco afetaram a análise qualitativa, enquanto distorções de positivas e negativas de 10° exerceram influência significativa mediante análise quantitativa, dificultando o processo de mensuração. A maioria das técnicas forenses para a análise dos seios frontais consiste da mensuração de distâncias morfológicas. Assim, distorções na angulação vertical de radiografias PA do crânio, de aproximadamente 10° , ou mais, devem ser evitadas para que possam se executar identificações comparativas com maior acurácia.

Palavras-chave: seios frontais, técnica radiográfica, antropologia forense, identificação humana.

Introduction

Forensic radiological analysis is a common procedure in human identifications, specifically in cases of carbonized and putrefied bodies and skeletal remains (ARBENZ, 1988; VANRELL, 2009). Although human identifications are classically performed by fingerprint

analysis, in several situations the soft tissues are not preserved and other alternative pathways, such as dental and anthropological examinations, are required (SILVA et al., 2008). Ante-mortem (AM) medical or dental radiographs within this context are highly relevant for further comparison with post-mortem (PM) records (ARBENZ, 1988).

Several anatomical areas of the body, such as the arms, forearms, chest and skull, provide valuable identification information through radiological analysis (CAMERIERI et al., 2005; KAHANA; HISS, 1999; SILVA et al., 2007; WOOD, 2008). There are four pairs of paranasal sinuses of forensic interest in the skull, namely, frontal, maxillary, sphenoidal and ethmoidal sinuses (NAMBIAR et al., 1999). Among the paranasal sinuses, the morphology of the frontal pairs may be clearly observed on posteroanterior radiographs. Caldwell's technique, which consists of supporting the head or skull in a horizontal plane, and thus enabling an adequate view for morphological analysis, is applicable to standardize PA imaging acquisition (CAMARGO JR. et al., 2007).

One of the main advantages in analyzing frontal sinuses is due to the frontal bone protection against external factors, such as trauma and decomposition, which makes PM examination highly reliable. Moreover, the frontal sinuses provide a unique morphological value for human identification, very much similar to the role of fingerprints (CAMERIERI et al., 2005).

The frontal sinuses are frequent in 96% of the population, with a bilateral position, distinct shape, dimensions and volume (CAMARGO et al., 2007; MONTOVANI et al., 2006). The first radiographic signs of the frontal sinuses formation occur at the age of six, and they are completely developed within the subjects' 10 – 20-year-old bracket (CAMERIERI et al., 2005; MONTOVANI et al., 2006; SCHULLER, 1943).

The feasibility of identifying a person by comparing radiographs of the frontal sinuses was first suggested by Schuller (1943). Later, Ribeiro (2000) developed a method based on the measurement of standardized distances of the frontal sinuses in 500 PA radiographs, and thus a quantitative analysis based on the height and width of both sinuses.

The manipulation of the head or skull is necessary for the PA PM radiographic imaging acquisition. It is expected that during this process variations on the vertical angle of x-ray incidence provide image distortion, hampering further comparative human identification (CAMARGO et al., 2007). Within this context, current research analyzes the forensic implications of the morphological variations of the skull's frontal sinuses in PA radiographs, by regularly modifying the vertical angle of x-ray incidence during Caldwell's technique.

Material and methods

The present research was undertaken with the approval of the Committee of Ethics in Research of the Federal University of Goiás, Goiânia, Goiás State, Brazil, under Protocol number: 195/2012.

A dry skull, with well-preserved skull-cap and facial bones, featuring anthropological characteristics of an adult male, was selected from the collection of the Department of Oral Diagnosis of the Dentistry School, Federal University of Goiás, and used to simulate PM radiographic examinations of skeletal remains. The skull underwent a standard PA radiograph according to Caldwell's technique, which consists of positioning the Frankfurt horizontal plane parallel to the floor (0°). The Frankfurt horizontal plane was demarcated on the skull by fixing a 0.9-mm-diameter stainless steel wire from the higher point of the external acoustic meatus to the lower point of the orbit (Figure 1).

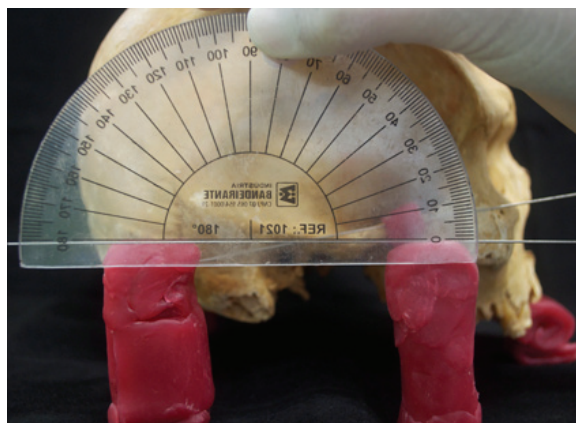


Figure 1. Determining Frankfurt's horizontal plane parallel to the floor.

Figure 1 illustrates the determination of Frankfurt's horizontal plane by positioning a stainless steel wire from highest point of the external acoustic meatus to the lowest point of the orbit, parallel to the floor. An additional wire was positioned to determine the variation of the vertical angle, calculated by protractor.

The radiographic procedure was performed using a MMR radiographic device (Villa Sistemi Medicali®, Buccinasco, Milan, Italy). The addressed imaging protocol consisted of Kv: 70 and radiographic exposure of 0.60 seconds. The radiographic pellicles were automatically processed into an AT 2000XR (Air Techniques®, Melville, New York, USA) film processor.

After the acquisition of a standard PA radiograph, eight other PA radiographs were taken by regularly varying the vertical angle from +10° to

+40° (Figure 2) and from -10° to -40° (Figure 3), using a protractor. For positive angle distortions, a wax block was placed under the anterior area of the alveolar bone. For negative angle distortions, a wax block was placed under the external occipital protuberance.

In Figure 2, image A shows standard PA radiograph (0°). Images B, C, D and E represent vertical angles variations at +10°, +20°, +30° and +40°, respectively.

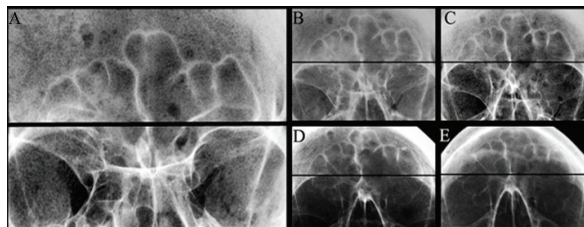


Figure 2. Positive variations of the vertical angle.

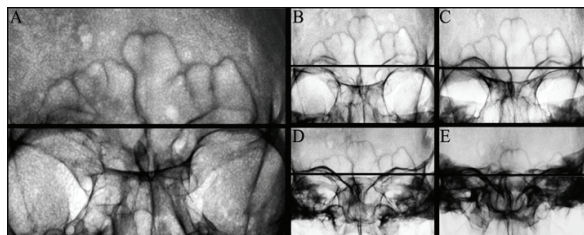


Figure 3. Negative variations of the vertical angle.

In Figure 3, image A represents standard PA radiograph (0°). Images B, C, D and E represent vertical angles variations at -10°, -20°, -30° and -40°, respectively.

Radiographs were then analyzed qualitatively and quantitatively on a light box. The qualitative analysis revealed the distribution of the lobes and septa and the frontal sinuses area (Figure 4).

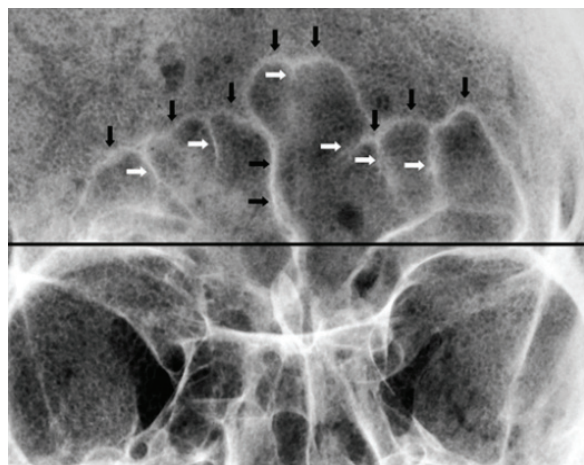


Figure 4. Detection of frontal sinus lobes and septa.

In Figure 4, vertical black arrows indicate the lobes in the two frontal sinuses. Horizontal black arrows indicate the septa inter-sinuses. White arrows indicate the septa in the two frontal sinuses.

Measurements based on method by Ribeiro (2000) were performed for quantitative analysis. The area of interest addressed in the above-mentioned method is placed above the orbit's upper limit. Thus, a horizontal line was drawn between the upper limits of the two orbits. Measurements took into consideration the distances between the highest point of the sinus and the horizontal line on the upper limit of the orbits, bilaterally. Further, the distances between the lateral highest points of the sinuses and the referred to horizontal line were also calculated (Figure 5).

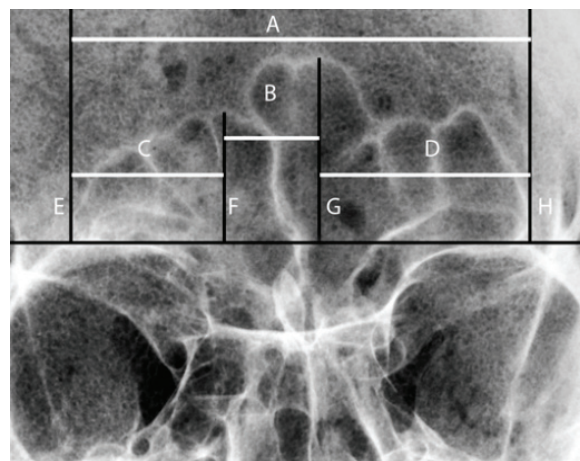


Figure 5. Frontal sinus analysis, following Ribeiro (2000).

According to Ribeiro (2000), a baseline is drawn horizontally on the upper limit of both orbit cavities (Figure 5). Line E indicates the lateral limit of the right frontal sinus; line H indicates the lateral limit of the left frontal sinus; line F passes from the highest point of the right frontal sinus to the base line; line G passes from the highest point of the left frontal sinus to the base line. Line A represents the measurement of the diameter of the frontal sinuses (distance between E and H). Line B represents the measurement between the highest points of the frontal sinuses (distance between F and G). Line C represents the measurement between the lateral limit of the right frontal sinus and the vertical line marking the highest point of the right frontal sinus (distance between E and F). Line D represents the measurement between the lateral limit of the left frontal sinus and the vertical line marking the highest point of the left frontal sinus (distance between G and H).

Results

In qualitative analysis, the same amount of lobes and septa, for both sides, were observed in all positive angle distortions ($+10^\circ$ to $+40^\circ$) (Table 1). When negative angle distortions were taken into account, only interval -10° presented the same number of lobes and septa if compared to the standard PA radiograph. Angle intervals between -20° and -40° severely distorted the image, without any positive identification (when a qualitative comparison is made with the standard PA radiograph).

Table 1. Qualitative analysis performed on PA radiographs with vertical angle distortions.

Angle distortion	Right lobes	Right septa	Left lobes	Left septa
$+40^\circ$	3	3	4	5
$+30^\circ$	3	3	4	5
$+20^\circ$	3	3	4	5
$+10^\circ$	3	3	4	5
0°	3	3	4	5
-10°	3	3	4	5
-20°	3	3	4	5
-30°	3	3	3	5
-40°	2	2	4	4

From the quantitative results obtained by Ribeiro's method (2000) (Table 2), a constant value (K) was calculated for all the items at all angle intervals (Table 3). To calculate K, the measurement results obtained in the angle distortions were divided by the measurements obtained in the standard radiographs. The constants presented a regular distribution on positive distortions. In negative distortions, constants A and D were regular for the angle intervals between -10° and -30° . Constants B and C were regular from -10° to -20° .

Table 2. Quantitative analysis performed on PA radiographs with vertical angle distortions, following measurements by Ribeiro (2000).

Angle distortion	A	B	C	D
$+40^\circ$	81 mm	11 mm	23 mm	47 mm
$+30^\circ$	81 mm	12 mm	25 mm	44 mm
$+20^\circ$	83 mm	17 mm	21 mm	45 mm
$+10^\circ$	80 mm	15 mm	21 mm	44 mm
0°	77 mm	14 mm	22 mm	41 mm
-10°	79 mm	15 mm	20 mm	44 mm
-20°	77 mm	15 mm	20 mm	42 mm
-30°	77 mm	14 mm	19 mm	44 mm
-40°	59 mm	10 mm	9 mm	40 mm

Table 3. Constant values (K) calculated by dividing each measurement in Table 2 by each measurement obtained from the quantitative analysis of standard PA (0°).

Angle distortion	K (A)	K (B)	K (C)	K (D)
$+40^\circ$	1.05	0.78	1.04	1.14
$+30^\circ$	1.05	0.85	1.13	1.07
$+20^\circ$	1.07	1.21	0.95	1.09
$+10^\circ$	1.03	1.07	0.95	1.07
-10°	1.02	1.07	0.90	1.07
-20°	1.00	1.07	0.90	1.02
-30°	1.00	1.00	0.86	1.07
-40°	0.76	0.71	0.40	0.97

Discussion

Current forensic routine widely employs the frontal sinuses for identification purposes. Most of the developed techniques in the analysis of frontal sinuses address the quantitative measurement of standardized distances, manually or digitally. Zhang et al. (2011) validated a specific coding system based on standard measurement and shape of CT images of the frontal sinuses. The authors concluded that the frontal sinuses provide reliable information for comparative human identification due to their uniqueness, excluding gender differentiation in reconstructive identification. Contrastingly, Lee et al. (2010) and Tatlisumak et al. (2008) reported a higher proportion of frontal sinuses dimensions in males than in females. Further, Yun et al. (2011) provided valuable data for reconstructive human identifications correlating the frontal sinuses development to the aging process in Korean children and sub-adults. On the other hand, current study investigated both qualitative and quantitative parameters and showed that the combination of both approaches during the radiographic analysis of the frontal sinuses provides optimized results for comparative human identifications, as previously expected (SCHULLER, 1943). It may be observed that qualitatively the frontal sinuses' morphology and the number of lobes and septa were constant in 5, within a total of eight different PA radiographic angulations ($+10^\circ$ to $+40^\circ$ and -10°), when compared to the standard PA radiograph (0°). Quantitatively, the absolute values of the sinuses measurements revealed different results when compared to the standard PA radiograph for each angle interval of distortion. The above shows that different angle distortions may modify the real distances between the focused points and thus hamper the measuring process. In addition, higher negative distortions in the vertical angle (-30° and -40°), such as flatness of the frontal sinuses and reduction of the number of lobes and septa, provide severe limitations in the qualitative-quantitative analysis of the sinuses. These limitations occur because the superior wall of the orbits (used as horizontal parameter in Ribeiro's method) in negative angle distortions is superposed by other anatomical bone structures. The alteration in the sinuses morphology and the superimposition of bone structures become directly and proportionally worse in higher negative distortions in the vertical angle.

In this context, the forensic professional working in human identifications, especially when comparing

frontal sinuses, must be aware of the techniques involved during the radiographic acquisition (SILVA et al., 2009a and b). The present survey demonstrates that different intervals of distortions in the vertical angle slightly compromise the qualitative analysis of the frontal sinuses. On the other hand, even low vertical angle distortions may severely compromise the quantitative analysis of the frontal sinuses by modifying the sinus morphology and impair measuring techniques.

Conclusion

It is highly relevant to note that subjective analysis of the frontal sinuses, such as the qualitative approach, hardly detects any morphological alterations from angle distortions, even by trained experts. Contrastingly, objective analysis, such as the quantitative approach, easily detects morphological alterations by revealing differences in measured reference parameters when compared to the standard radiograph. Most of the reliable techniques for the analysis of the frontal sinuses, in the forensic practice, address measurements of standardized distances. Thus, even slight distortions in the vertical angle should be avoided in PM PA radiographs for adequate comparative human identifications.

Acknowledgements

The authors would like to thank the Department of Imaging Diagnosis of the Dentistry School, Federal University of Goiás, Brazil.

References

- ARBENZ, G. O. **Medicina legal e antropologia forense**. 1. ed. Rio de Janeiro: Atheneu, 1988.
- CAMARGO, J. R.; DARUGE, E.; PRADO, F. B.; CARIA, P. H. F.; ALVES, M. C.; SILVA, R. F.; DARUGE JUNIOR, E. The frontal sinus morphology in radiographs of Brazilian subjects: its forensic importance. **Journal of Morphological Sciences**, v. 24, n. 4, p. 239-243, 2004.
- CAMERIERI, R.; FERRANTE, L.; MIRTELLA, D. Frontal sinuses for identification: quality of classifications, possible error e potential connections. **Journal of Forensic Sciences**, v. 50, n. 4, p. 770-773, 2005.
- KAHANA, T.; HISS, J. Forensic radiology. **The British Journal of Radiology**, v. 72, n. 854, p. 129-33, 1999.
- LEE, M. K.; SAKAI, O.; SPIEGEL, J. H. CT measurement of the frontal sinus – gender differences and implications for frontal cranioplasty. **Journal of Craniomaxillofacial Surgery**, v. 38, n. 7, p. 494-500, 2010.
- MONTOVANI, J. C.; NOGUEIRA, E. A.; FERREIRA, F. D.; LIMA NETO, A. C.; NAKAJIMA, V. Surgery of frontal sinus fracture: epidemiological study and analysis of techniques. **Revista Brasileira de Otorrinolaringologia**, v. 72, n. 2, p. 204-209, 2006.
- NAMBIAR, P.; NAIDU, M. D. K.; SUBRAMANIANN, K. Anatomical variability of the frontal sinuses and their application forensic identification. **Clinical Anatomy**, v. 12, n. 1, p. 16-9, 1999.
- RIBEIRO, F. A. Q. Standardized measurements of radiographic films of the frontal sinuses: an aid to identifying unknown persons. **Ear, Nose and Throat Journal**, v. 79, n. 1, p. 26-8, 30, 32-3, 2000.
- SILVA, R. F.; PARANHOS, L. R.; MARTINS, E. C.; FERNANDES, M. M.; DARUGE JR., E.; DARUGE, E. Association of two techniques for the radiographic analysis of frontal sinus for human identification. **Revista Sul-Brasileira de Odontologia**, v. 6, n. 3, p. 311-315, 2009a.
- SILVA, R. F.; PRADO, F. B.; CAPUTO, I. G.; DEVITO, K. L.; BOTELHO, T. L.; DARUGE JR., E. The forensic importance of frontal sinus radiographs. **Journal of Forensic and Legal Medicine**, v. 16, n. 1, p. 18-23, 2009b.
- SILVA, R. F.; PINTO, R. N.; FERREIRA, G. M.; DARUGE JR., E. Importance of frontal sinus radiographs for human identification. **Brazilian Journal of Otorhinolaryngology**, v. 74, n. 5, p. 798, 2008.
- SILVA, R. F.; PINTO, R. N.; MENDES, S. D. S. C.; MARINHO, D. E. A.; TEIXEIRA, E. A. Forensic importance of hand and wrist radiographs for human identification. **Revista Imagem**, v. 29, n. 4, p. 165-167, 2007.
- SCHULLER, A. A note on the identification of skulls by x-ray pictures of the frontal sinuses. **Medical Journal of Australia**, v. 1, n. 1, p. 554-557, 1943.
- TATLISUMAK, E.; OVALI, G. Y.; ASIRDIZER, M.; ASLAN, A.; OZYURT, B.; BAYINDIR, B.; TARHAN, S. CT study on morphometry of frontal sinus. **Clinical Anatomy**, v. 21, n. 4, p. 287-293, 2008.
- VANRELL, J. P. **Odontologia legal e antropologia forense**. 2. ed. Rio de Janeiro: Guanabara Koogan, 2009.
- WOOD, R. E. Forensic aspects of maxillofacial radiology. **Forensic Science International**, v. 159, n. 1, p. 47-55, 2006.
- YUN, I. S.; KIM, Y. O.; LEE, S. K.; RAH, D. K. Three-dimensional computed tomographic analysis of frontal sinus in Asians. **Journal of Craniofacial Surgery**, v. 22, n. 2, p. 462-467, 2011.
- ZHANG, H. X.; YANG, C. B.; GUO, L.; DENG, Z. H. Forensic Identification by coding of frontal sinus characteristics of CT. **Fa Yi Xue Za Zhi**, v. 27, n. 1, p. 13-16, 2011.

Received on March 25, 2013.

Accepted on April 23, 2013.

License information: This is an open-access article distributed under the terms of the Creative Commons Attribution License, which permits unrestricted use, distribution, and reproduction in any medium, provided the original work is properly cited.