



ARTIGO | ARTICLE

## New record of *Dyoctophyma renale* in the maned wolf (*Chrysocyon brachyurus*) in the State of Goiás, Brazil

*Novo registro do Dyoctophyma renale em lobo-guará (Chrysocyon brachyurus) no estado de Goiás*

Rosana Talita Braga<sup>1</sup>

Carly Vynne<sup>2</sup>

Marinês Conceição Rieth Corrêa<sup>3</sup>

Rafael Dias Loyola<sup>1</sup>

### ABSTRACT

The maned wolf (*Chrysocyon brachyurus*) is the largest canid of South America and is classified as Near Threatened by International Union for Conservation of Nature. This species has a large home range and often occurs in areas where human-wildlife conflicts are likely to take place. The maned wolf has been previously shown to be infected by a diversity of parasite species. Here we present a new record of the giant kidney worm (*Dyoctophyma renale* Goeze 1972) in the maned wolf found in the State of Goiás, central Brazil. This parasite has been also found in other Brazilian states and has been shown to be linked to *C. brachyurus* mortality rates. The occurrence of this parasite in the State of Goiás is a crucial piece of information for evaluating the distribution as well as the potential influence of this parasite on the plight of the maned wolf in Brazil.

**Key words:** Maned wolf, Brazil. Giant kidney worm. Nematode. Parasitology. Cerrado.

### RESUMO

*O lobo-guará (Chrysocyon brachyurus) é o maior canídeo da América do Sul, sendo classificado como quase ameaçado de extinção pela União Internacional para a*

<sup>1</sup> Universidade Federal de Goiás, Instituto de Ciências Biológicas, Departamento de Ecologia, Laboratório de Ecologia Aplicada e Conservação. Caixa Postal 131, 74001-970, Goiânia, GO, Brasil. Correspondência para/Correspondence to: R.D. LOYOLA. E-mail: <avispa@gmail.com>.

<sup>2</sup> University of Washington, Department of Biology, Seattle, Washington, EUA.

<sup>3</sup> Universidade Federal de Goiás, Fundação Educacional de Jataí. Goiânia, GO, Brasil.

*Conservação da Natureza e dos Recursos Naturais e como uma espécie vulnerável pelo Instituto Brasileiro do Meio Ambiente e dos Recursos Naturais Renováveis. A espécie possui área de vida extensa, ocorrendo inclusive em áreas onde conflitos entre animais silvestres e populações humanas podem acontecer. Sabe-se que o lobo-guará pode ser infectado por diversos parasitas. Neste estudo, é apresentado um novo registro do verme gigante renal (Dyocotophyma renale Goeze 1972) encontrado em lobo-guará, no estado de Goiás. Esse parasita já foi encontrado em outros estados brasileiros, sendo associado a taxas de mortalidade em populações de lobo-guará. A ocorrência desse parasita no estado de Goiás é uma informação crucial para avaliar tanto a distribuição geográfica quanto a influência potencial desse parasita na sobrevivência do lobo-guará no Brasil.*

**Palavras-chave:** Lobo-guará, Brasil. Verme gigante renal. Nematóide. Parasitologia. Cerrado.

## INTRODUCTION

The maned wolf (*Chrysocyon brachyurus* Illiger 1811) is the largest canid in South America, and is listed as a CITES Appendix II species (Convention on International Trade in Endangered Species of Wild Fauna and Flora, 2009). It is also highlighted as Near Threatened (NT) species on the IUCN Red List (International Union for Conservation of Nature, 2009). The main threat to the persistence of wild maned wolf populations are habitat loss and fragmentation, road kills, and contact with domestic dogs (Rodden et al., 2004). Disease is also increasingly becoming recognized as an important threat (Deem et al., 2005). Parasites are known to infect maned wolves and to cause mortality in captivity (Maia & Gouveia, 2002), but their impact on wild populations is largely unknown.

The giant kidney worm (*Dyocotophyma renale* Goeze 1972) is the largest known nematode infesting the maned wolf. The kidney worm is globally distributed and has been frequently described as parasitizing both domestic and wild carnivores (Barriga, 1982; Ribeiro et al., 2007). Beyond *C. brachyurus*, *D. renale* parasites other species of wild carnivores such as the bush dog (*Speothos venaticus*) and the South American coati (*Nasua nasua*), among others (Vieira et al., 2008).

The parasite usually infects the right kidney, which becomes severely inflamed or totally atrophied (Matera et al., 1968). Adult kidney-worm size varies between 14 and 103cm in length, and female worms

are larger than males (Barriga, 1982). The males have thin, transverse striations on the outer layer. Both sexes are blood red in colour, have round bodies, and are slightly tapered at the ends. The eggs are ellipsoid with a hard covering and small depressions, and are often found in parasitized animals' urine (Barriga, 1982).

The life cycle of *D. renale* presents three basic life forms: eggs, infectious larvae, and female and male adults. For completing this cycle the kidney worm needs (1) a vertebrate mammal host, (2) an intermediate host, which is a free-living invertebrate, and (3) a paratenic host, usually fishes, amphibians or crustaceans (in paratenic hosts the larvae do not develop into adults). The infestation of *D. renale* occurs by the consumption of an intermediate or paratenic host (Barriga, 1982). As adults develop, the eggs are eliminated in the urine of the vertebrate host, mature slowly in water, and begin a new cycle (Barriga, 1982). The infection of kidney worm may cause host death due to kidney failure, as it gradually consumes renal tissues.

The State of Goiás is characterized by remnants of *Cerrado* surrounded by pasture (both native and cultivated) and agricultural areas. The current status and trends of maned wolf populations in the region remain unknown, and there is little knowledge on how landscape change affects these populations. The Brazilian *Cerrado* has undergone a severe habitat fragmentation, resulting in several small and isolated remnants distributed across the landscape, being classified as a biodiversity hotspot

due to such habitat loss and high plant endemism (Myers *et al.*, 2000). This landscape scenario forces the wolves to move among remnants and to face the multiple hazards that are associated with the intermediate matrix, such as poaching, road kills, agrochemicals, and other pollutants. They become also more vulnerable to infections caused by parasites.

## MATERIAL AND METHODS

An approximately four year-old male of *C. brachyurus* was brought to a captive rehabilitation centre for wild animals in the city of Jataí, in the state *Goiás*, after being hit by a car on a federal highway (BR-158). In captivity, the wolf remained three days under observation and medical attention before its death, presumably resulting from injuries provoked by the accident. The animal was then frozen until necropsy. During necropsy, a longitudinal cut was made in the right and left kidneys in order to evaluate the tissue structure and any possible abnormalities. The tissues along with the macroscopic findings were kept in 70% alcohol.

## RESULTS AND DISCUSSION

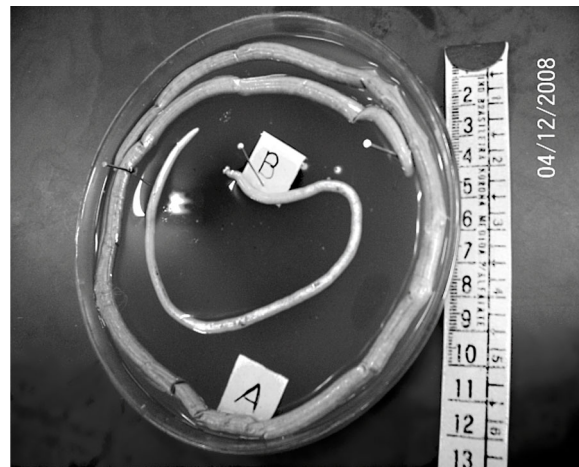
We detected a new record of *D. renale* in a free-living *C. brachyurus*. During the necropsy, it was observed that virtually all tissue of the right kidney had been consumed by the kidney worm, leading to kidney atrophy. This kidney contained seven adult giant kidney worms, being four females and three males varying from 14 to 45cm in length (Figure 1). The left kidney was parasite-free, but macroscopically presented a hypertrophied structure, characterized by the hyper function required of this uninfected kidney.

Given that the parasite is a known threat to maned wolf survival, and given that this region is thought to be a stronghold of the global population of maned wolves, reporting of the giant kidney worm occurrence in wolves in this region is of great importance. *D. renale* has a worldwide distribution and has also been recorded in humans and dogs,

which characterizes *D. renale* as a potentially zoonotic parasite (Hanjan *et al.*, 1968; Barriga, 1982; Ribeiro *et al.*, 2007).

The first record of *D. renale* in *C. brachyurus* in Brazil was done in 1860 (Leite *et al.*, 2005). In the state of *Goiás*, such parasitism was recorded for the first time by Carneiro *et al.* (1974). However, our knowledge on *D. renale* distribution and its level of infestation in wild canid populations in *Goiás* is extremely scarce. The destruction of native habitats has made free-living animals more vulnerable to parasitism. Wild canids are potentially susceptible to some common illnesses found in domestic dogs (Fowler, 1986).

In epidemiological studies, parasitic diseases are cited as one of the principal causes of maned wolf's mortality in captivity (Maia & Gouveia, 2002). In the first two decades of *C. brachyurus* studies in Brazil, there have been indications that *D. renale* infection can be very dangerous to wild animals' health (Dietz, 1984). Intestinal parasites cause injury to the intestinal lining, leading to poor absorption of nutrients (Northrop-Clewes *et al.*, 2001). Hence, infection by *D. renale* may debilitate the host, reducing its resistance to injury or disease, and thus contributing to host mortality.



**Figure 1.** (A) Female and (B) male of the giant kidney worm (*Dycoctophyma renale*) found in the parenchyma of the right kidney of a maned wolf (*Chrysocyon brachyurus*) during the necropsy. Necropsy performed at the captive rehabilitation centre for wild animals. Jataí (GO), Brazil (2008).

The maned wolf's diet constitutes primarily of fruit, birds, marsupials, and rodents (Rodden et al., 2004), and these items do not fit as intermediate or transport host. However, as the species foraging behaviour is opportunistic (Rodden et al., 2004), accidental ingestion of contaminated prey items are likely to occur. The region in which the animal was found is surrounded by waterways, supporting the hypothesis of the ingestion of water containing parasite eggs delivered by amphibians or infected fishes (transport hosts).

It has been suggested that the presence of fruits of *Solanum lycocarpum* (Solanaceae; the so-called *lobeira*), the principal food item found in the diet of the maned wolf (Santos et al., 2003), might help it to get rid of parasites such as *D. renale*, as the ingestion of these fruits may produce inhibitory effects on the parasite development (Silveira, 1969). Therefore, it is imperative to evaluate if the regional distribution of maned wolf populations matches those of *S. lycocarpum* populations within *Goias*. Another alternative is to test the anti-parasitic potential of other fruits that are also found in the diet of maned wolves within the region.

The occurrence of *D. renale*, in combination with habitat destruction and direct persecution of wolves, may represent a threat to the survival of maned wolf populations in the wild. Its occurrence and infestation rates in wild populations require further study. Moreover, human population should be examined given that the parasite has already been implicated as zoonotic and thus risks infecting human population of this region as well (Sujatha & Fernando, 1983).

New guidelines for the conservation of the maned wolf should include current knowledge on *D. renale* biology and regional distribution. It is also necessary to develop studies about its occurrence in other areas of the state, in order to consider the likely level of infestation in wild maned wolf populations. One way to accomplish this would be the creation of a reception centre for wild animals' necropsy, which would ensure a standard practice for evaluating the presence and distribution of this parasite in maned

wolves across the State of *Goias*. Better understanding about the importance of this parasite for the persistence of local maned wolf populations would entail great benefits for conservation and management of this unique and endangered canid species.

## REFERENCES

- Barriga, O.O. (1982). Dyoctophymosis. In: Schultz M.G. (Ed.). *Handbook series in zoonoses*. Florida: CRC. p.83-92.
- Carneiro, J.R.; Pereira, E. & Puglia, L.R. (1974). Nota sobre a ocorrência de *Dyoctophyme renale* (Goeze, 1782) em Goiânia. *Revista de Patologia Tropical*, 3(2):215-6.
- Convention on International Trade in Endangered Species of Wild Fauna and Flora. (2009). Available from: <<http://www.cites.org/eng/resources/speces.html>>. (accessed 10 July 2009).
- Deem, D.V.M.S.L. & Emmons, L.H. (2005). Exposure of free-ranging maned wolves (*Chrysocyon brachyurus*) to infectious and parasitic disease agents in the Noel Kempff Mercado national park, Bolivia. *Journal of Zoo and Wildlife Medicine*, 36(2):192-7.
- Dietz, J.M. (1984). Ecology and social organization of the maned wolf (*Chrysocyon brachyurus*). *Smithsonian Contributions to Zoology*, 392(1):1-24.
- Fowler, M.E. (Ed.) (1986). *Zoo and Wild Animal Medicine*. 2<sup>nd</sup> ed. Philadelphia: Saunders. v.48.
- Hanjan, A.; Sadighan, A.; Mikakhfar, B. & Arfaa, F. (1968). The first report of human infection with *Dyoctophyma renale* in Iran. *Transactions of the Royal Society of Tropical Medicine and Hygiene*, 62(5):647-8.
- Leite, L.C.; Círio, S.M.; Diniz, J.M.F.; Luz, E.; Navarro-Silva, M.A.; Silva, A.W.C.; Leite, S.C.; Zadorosnei, A.C.; Musiat, K.C.; Veronesi, E.M. & Pereira, C.C. (2005). Lesões anatomopatológicas presentes na infecção por *Dyoctophyma renale* (Goeze, 1782) em cães domésticos (*Canis familiaris*, Linnaeus, 1758). *Archives of Veterinary Science*, 10(1):95-101.
- Maia, O.B. & Gouveia, A.M.G. (2002). Birth and mortality of maned wolf *Chrysocyon brachyurus* (ILLIGER, 1811) in captivity. *Brazilian Journal of Biology*, 62(1):25-32.
- Matera, E.A., Saiba, A.M., & Matera, A. (1968). The occurrence of dyoctrphymiasis in the Maned wolf (*Chrysocyon brachyurus*). *International Zoo Yearbook*, 8:24-7.
- Myers, N.; Mittermeier, R.A.; Mittermeier, C.G.; Fonseca, G.A.B. & Kent, J. (2000). Biodiversity hotspots for conservation priorities. *Nature*, 403:853-8.

- Northrop-Clewes, C.A.; Rousham, E.K.; Mascie-Taylor, C.G.N. & Lunn, P.G. (2001). Anthelmintic treatment of rural Bangladeshi children: effect on host physiology, growth, and biochemical status. *American Journal of Clinical Nutrition*, 73(1):53-60.
- Ribeiro, T.L.D.; Bracaraense, A.P.F.R.L.; Reis, A.C.F.; Yamamura, M.H. & Headley, S.A. (2007). Giant kidney worm (*Dioctophyma renale*) infections in dogs from Northern Paraná, Brazil. *Veterinary Parasitology*, 145(3-4):366-70.
- Rodden, M.; Rodrigues, F. & Bestelmeyer, S. (2004). Maned wolf (*Chrysocyon brachyurus*). In: Sillero-Zubiri, C.; Hoffmann, M. & Macdonald, D.W. (Ed.). *Canids: foxes, wolves, jackals and dogs*. IUCN/SSC Canid Specialist Group. Gland: INCN. p.38-44.
- Santos, E.F.; Setz, E.Z.F. & Gobbit, N. (2003). Diet of maned wolf (*Chrysocyon brachyurus*) and its role in seed dispersal on a cattle ranch in Brazil. *Journal of Zoology*, 260:203-8.
- Silveira, E.K.P. (1969). O lobo-guará (*Chrysocyon brachyurus*): possível ação inibidora de certas solanáceas sobre o nematóide renal. *Vellozia*, 7:58-60.
- Sujatha, S.E. & Fernando, M.B.B.S. (1983). The Giant Kidney Worm (*Dioctophyma renale*) infection in man in Australia. *Journal of Surgeon Pathology*, 7(3):281-4.
- União Internacional para a Conservação da Natureza e dos Recursos Naturais. (2009). IUCN red list of threatened species. Version 2009.1. Available from: <<http://www.iucnredlist.org>>. (accessed 10 July 2009).
- Vieira, F.M.; Luque, J.L. & Muniz-Pereira, L.C. (2008). Checklist of helminth parasites in wild carnivore mammals from Brazil. *Zootaxa*, 1721:1-23.

Received on: 18/11/2009

Approved on: 1/2/2010

