

RESEARCH

Open Access



# Is axillary surgery still justified in DCIS diagnosed via vacuum-assisted biopsy?

Marcellus do Nascimento Moreira Ramos<sup>1,2</sup>, André Mattar<sup>2,3\*</sup>, Marcelo Antonini<sup>1,3</sup>, Felipe Zerwes<sup>3,4,5</sup>, Felipe Cavagna<sup>2</sup>, Francisco Pimentel Cavalcante<sup>3,6</sup>, Eduardo Camargo Millen<sup>3,7</sup>, Fabricio Palermo Brenelli<sup>3,8</sup>, Antonio Luiz Frasson<sup>3,9</sup>, Marcelo Madeira<sup>10</sup>, Andressa Gonçalves Amorim<sup>1</sup>, Marina Diógenes Teixeira<sup>1,2</sup>, Marina Fleury de Figueiredo<sup>2</sup>, Larissa Chrispim de Oliveira<sup>2</sup>, Leonardo Ribeiro Sorares<sup>11</sup>, Gil Facina<sup>12</sup>, Rogerio Fenile<sup>13</sup>, Ruffo de Freitas Júnior<sup>10,14</sup>, Renata Arakelian<sup>2,15</sup>, Marcela Bonalumi dos Santos<sup>2,16</sup>, Henrique Lima Couto<sup>17</sup>, Renata Montarroyos Leite<sup>18,19</sup>, Pedro Paulo de Andrade Gomes<sup>2</sup>, Gabriela de Oliveira Gomes<sup>2</sup>, Luiz Henrique Gebrim<sup>20</sup>, Reginaldo Guedes Coelho Lopes<sup>1</sup> and Juliana Monte Real<sup>1</sup>

## Abstract

**Background** The role of axillary surgery in ductal carcinoma in situ (DCIS) remains controversial, particularly for cases diagnosed via vacuum-assisted biopsy (VAB), which may reduce “upstage” to invasive disease. This study evaluates the incidence of axillary metastasis and pathologic upstaging in DCIS to identify subgroups where axillary staging can be safely omitted.

**Methods** A retrospective cohort of 494 patients with pure DCIS diagnosed by VAB (2011–2019) was analyzed. Patients were stratified by age, nuclear grade, comedonecrosis, and surgical approach (breast-conserving surgery [BCS] vs. mastectomy). Axillary management included sentinel node biopsy (SNB), axillary dissection (AD), or omission. Multivariate logistic regression identified predictors of axillary surgery and upstaging to invasive carcinoma.

**Results** Most patients underwent BCS (72.7%), with axillary evaluation performed in 35.1% of BCS cases versus 91.9% of mastectomies ( $p < 0.001$ ). Only 3.8% (19/494) were upstaged to invasive carcinoma, and nodal involvement occurred in 1.2% (3/250) of axillary procedures—all in patients with invasive foci on final pathology. No pure DCIS cases had nodal metastasis. Younger age ( $< 40$  years,  $p = 0.039$ ), high nuclear grade (grade 3,  $p = 0.006$ ), and mastectomy ( $p < 0.001$ ) independently predicted axillary surgery. Comedonecrosis and palpable lesions were associated with higher SNB rates but not nodal positivity.

**Conclusions** Routine axillary surgery is unnecessary in VAB-diagnosed DCIS. Omission of SNB appears safe for patients undergoing BCS without high-risk features (palpability, high grade). Axillary staging may be reserved for mastectomy candidates or those with suspicious imaging of invasive disease.

**Keywords** DCIS, Sentinel lymph node biopsy, Axillary surgery, Vacuum-assisted biopsy, De-escalation

\*Correspondence:  
André Mattar  
mattar.andre@gmail.com

Full list of author information is available at the end of the article



© The Author(s) 2025. **Open Access** This article is licensed under a Creative Commons Attribution-NonCommercial-NoDerivatives 4.0 International License, which permits any non-commercial use, sharing, distribution and reproduction in any medium or format, as long as you give appropriate credit to the original author(s) and the source, provide a link to the Creative Commons licence, and indicate if you modified the licensed material. You do not have permission under this licence to share adapted material derived from this article or parts of it. The images or other third party material in this article are included in the article's Creative Commons licence, unless indicated otherwise in a credit line to the material. If material is not included in the article's Creative Commons licence and your intended use is not permitted by statutory regulation or exceeds the permitted use, you will need to obtain permission directly from the copyright holder. To view a copy of this licence, visit <http://creativecommons.org/licenses/by-nc-nd/4.0/>.

## Introduction

Ductal carcinoma in situ (DCIS) represents a growing public health challenge, particularly with the expansion of breast cancer screening programs. Before the widespread adoption of screening mammography, DCIS was rare and typically presented symptomatically. This shift in detection has prompted ongoing debates about the optimal management of screen-detected DCIS, particularly regarding the necessity of axillary staging once it does not breach the myoepithelial layer, rendering it incapable of metastasizing [1]. However, the possibility of upstaging after surgery remains, as an undetected invasive component may coexist and only be identified in the final pathological assessment [2]. Axillary lymph node status remains the most powerful prognostic indicator for patients with invasive breast cancer. Currently, sentinel lymph node biopsy (SNB) is the standard of care for all cases of clinically negative lymph nodes in invasive breast cancer [3] and is also recommended for DCIS when invasive disease is suspected [4].

Before the advent of screening mammography, DCIS was almost exclusively diagnosed in symptomatic women presenting with a palpable nodule, nipple discharge, or as an incidental finding on a breast biopsy [5] accounting for only 1–2% of all breast cancer cases [6]. However, with the widespread implementation of population-based breast cancer screening programs and advancements in digital imaging, the detection rate of DCIS has increased dramatically, now representing 20–25% of all breast cancer diagnoses [7].

While routine axillary lymph node staging in DCIS is generally considered unnecessary, SNB remains selectively performed in cases with extensive disease, particularly when mastectomy is required. The primary rationale for SNB in DCIS is the possibility of an unrecognized invasive component, which could influence further treatment decisions.

Vacuum-assisted biopsy (VAB) mitigates this uncertainty by enabling larger tissue yields and lower underestimation rates (5–15% vs. 15–25% for CNB) [8, 9]. Yet, the necessity of axillary surgery in VAB-diagnosed DCIS—where invasive foci are reliably excluded—remains undefined. Prior studies conflate biopsy methods or lack power to identify low-risk subgroups [4, 10] perpetuating heterogeneous practices. For example, 19% of BCS patients in the U.S. undergo unnecessary SNB despite guideline discouragement [11] exposing them to lymphedema and sensory morbidity without survival benefit [12].

The necessity of SNB in invasive cancer has been a subject of ongoing debate. For small tumors, older patients, and particularly those with a negative axillary ultrasound, it is increasingly considered unnecessary [13, 14]. In the context of DCIS, the issue remains even

more controversial. The reported incidence of metastatic axillary lymph node involvement in patients with a preoperative diagnosis of DCIS ranges from 3 to 7.4%<sup>13</sup>. Identifying a subset of patients with a preoperative DCIS diagnosis who are at high risk of harboring an invasive component would be valuable in determining which individuals should undergo axillary staging and be considered candidates for SNB.

The aim of this study is to evaluate the necessity of axillary surgical approaches, including SNB and AD, in patients with DCIS. By analyzing retrospective data from a single institution, the study assesses the impact of different surgical treatments (mastectomy or breast-conserving surgery, BCS) on axillary management.

## Methods

### Study design and data source

This retrospective cohort study utilized real-world data (RWD) from the Women's Health Hospital, a reference center for breast and gynecologic cancer treatment in Brazil. The analysis was based on secondary data from the institutional database and was conducted following approval from the ethics committee. The study followed ISPE/ISPOR guidelines for exploratory real-world research [15]. Data from women diagnosed and treated at the hospital between January 2011 and December 2019 were included.

### Patients selection

All consecutive women diagnosed aged  $\geq 18$  years with DCIS by vacuum-assisted biopsy (VAB) between January 2011 and December 2019 were included to ensure a complete dataset with adequate clinical and pathological follow-up. As this was a retrospective, observational cohort study, no formal sample size calculation was performed. The final date of inclusion reflects the most recent period with fully validated and analyzable institutional records. All cases were diagnosed through VAB guided by mammography or ultrasonography. Eligibility required complete medical records covering diagnosis, treatment, and follow-up. Exclusion criteria included loss to follow-up and cases outside the study period. A total of 274 patients were excluded because they underwent diagnostic surgical excision as the initial approach rather than image-guided biopsy. This occurred primarily during the earlier years of the study period due to limited access to vacuum-assisted biopsy or in cases presenting with palpable lesions and inconclusive imaging findings. As the aim of this study was to assess axillary management in patients with DCIS confirmed preoperatively by VAB, these cases were excluded to preserve methodological consistency.

### Breast biopsy

All vacuum-assisted biopsies were performed using 9-gauge needles with the ATEC<sup>®</sup> Breast Biopsy System (Hologic Inc., USA). This approach allows high-volume sampling, which enhances diagnostic accuracy, particularly for non-palpable lesions and suspicious calcifications.

### Axillary approach

SNB was performed using blue dye alone and axillary dissection was defined in this study as the removal of six or more lymph nodes. In the majority of cases where dissection was performed, the indication was failure to identify a sentinel lymph node, which is a recognized limitation of the blue dye-only technique used in our institution. As a result, some procedures classified as axillary dissection may reflect extended sampling rather than formal level I–II dissections.

### Outcomes and clinical data

This study focused on axillary evaluation through SNB or AD in DCIS patients. Patients were stratified into three age groups based on clinical relevance to breast cancer screening practices in Brazil: <40 years (typically outside of routine screening programs), 40–49 years (transitional group with variable screening access), and ≥50 years (the primary target population for national screening initiatives). Although these categories resulted in uneven group sizes, they reflect real-world age-related differences in clinical presentation and healthcare access. We analyzed the surgeon's choice of breast and axillary surgery, diagnostic methods, and pathological features, including comedonecrosis and nuclear grade. All patients undergoing axillary evaluation had SNB performed using the patent blue technique or AD, with lymph nodes assessed via the H&E method. Axillary management was categorized as no intervention, SNB, or AD (defined as the removal of six or more lymph nodes) [16].

### Statistical analyses

Descriptive statistics were used to summarize baseline patient characteristics, including absolute and relative frequencies for categorical variables and mean, median, standard deviation, coefficient of variation, minimum, and maximum values for continuous variables. The Chi-square test was employed for univariate analysis to identify factors associated with axillary evaluation and type of surgery. Student's t-test was used to compare mean ages between groups. Multivariable logistic regression models were constructed to identify independent predictors of axillary intervention and radical surgery, with results expressed as odds ratios (OR) with 95% confidence intervals. The quality of regression models was assessed using the Hosmer-Lemeshow goodness-of-fit test and

Nagelkerke's  $R^2$  coefficient. All statistical tests were two-sided, with p-values < 0.05 considered statistically significant. Statistical analyses were performed using SPSS v26 (2019), Minitab 21.2 (2022), and Excel Office 2010.

### Ethics

This study was conducted in compliance with the ethical principles of the Declaration of Helsinki (<https://www.wma.net/policies-post/wma-declaration-of-helsinki/>) and was approved by the Research Ethics Committee (CAAE CAAE: 72387317.6.0000.0069) through Plataforma Brazil. Due to its retrospective nature, the requirement for informed consent was waived, ensuring the confidentiality and anonymity of patient data through record anonymization.

### Results

From 2011 to 2019, a total of 11,273 breast cancer patients were evaluated. Of these, the majority (10,349 patients, 92.6%) had invasive breast cancer and were not included in this analysis. The remaining 834 patients (7.4%) had a diagnosis of Ductal Carcinoma in Situ (DCIS). Among the DCIS patients, 430 were excluded from the study: 81 (10.3%) due to incomplete data, 75 (11.1%) due to loss to follow-up, and 274 (32.8%) because surgery was performed at diagnosis. This resulted in a final cohort of 494 DCIS patients included in the analysis. The final cohort was divided into three treatment groups: 243 patients (49.2%) received no lymph node intervention (Omitted group), 212 patients (42.9%) underwent Sentinel Node Biopsy (SNB group), and 39 patients (7.9%) underwent Axillary Dissection (AD group). The patient selection process and distribution of treatment approaches are illustrated in Fig. 1.

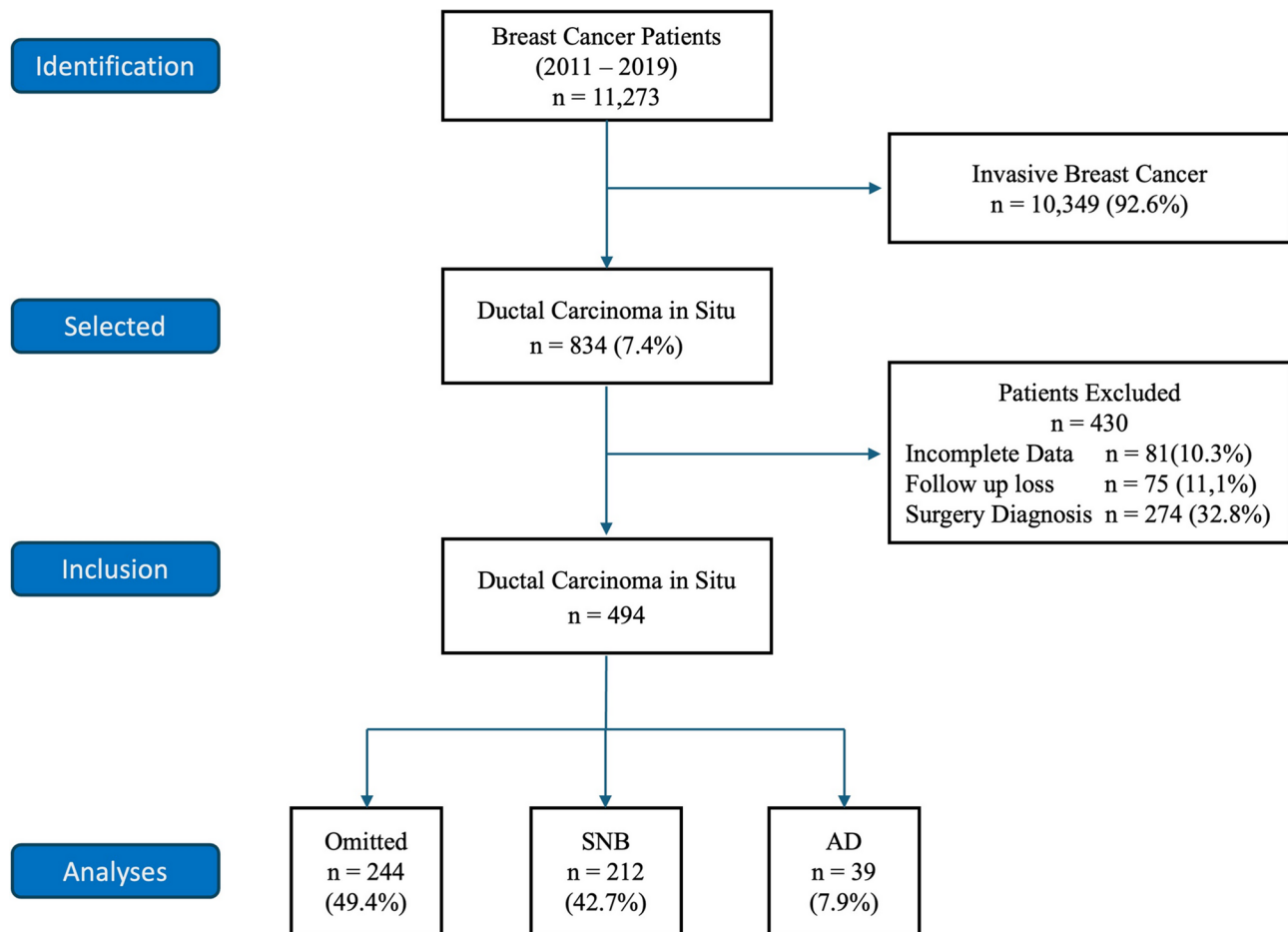
### Clinical and pathological characteristics

The study included 494 patients with DCIS, the majority of whom were 50 years or older (69.4%), while 25.9% were between 40 and 49 years, and only 4.7% were younger than 40.

Regarding tumor characteristics, nuclear grades 2 and 3 were nearly evenly distributed (47.6% and 47.7%, respectively), with only 4.7% classified as nuclear grade 1. Comedonecrosis was present in most cases (78.1%).

Immunohistochemical analysis was conducted in all of patients, revealing that 43.5% had hormone receptor-positive, HER2-negative tumors (HR+/HER2-), 8.5% had hormone receptor-negative, HER2-negative tumors (HR-/HER2-), 24.7% had hormone receptor-negative, HER2-positive tumors (HR-/HER2+), and 23.3% had hormone receptor-positive, HER2-positive tumors (HR+/HER2+).

Most patients (79.1%) were diagnosed through mammography screening, while 16.6% presented with a



**Fig. 1** Flowchart of included patients. **Legend:** SNB – sentinel node biopsy, AD – axillary dissection

palpable lesion, and 4.3% were identified via ultrasound. The most common mammographic finding was calcifications (73.1%), followed by nodules (20.4%), asymmetry (5.7%), and architectural distortion (0.8%).

In terms of surgical management, BCS was performed in 72.7% of patients, while 27.3% underwent mastectomy. For axillary management, 49.2% of patients did not undergo any axillary procedure, 42.9% underwent sentinel lymph node biopsy, and 7.9% had axillary dissection.

Post-surgical upstaging to invasive carcinoma occurred in 3.8% of cases, while 96.2% maintained a diagnosis of pure DCIS. These data are presented in Table 1.

#### Comparison of characteristics between patients with and without axillary surgery

Table 1 compares the clinical and pathological characteristics of patients who did not undergo axillary surgery ( $n = 244$ ) with those who underwent axillary procedures ( $n = 250$ ).

The mean age was significantly higher in the non-axillary surgery group ( $58.1 \pm 10.8$  years) compared to the axillary surgery group ( $54.2 \pm 10.7$  years) ( $p = 0.001$ ).

Among patients younger than 40 years, 73.9% underwent axillary surgery, while only 26.1% did not ( $p = 0.022$ ). Similarly, in the 40–49 age group, axillary surgery was more frequent (58.6% vs. 41.4%,  $p = 0.036$ ). Conversely, patients aged 50 or older were more likely to avoid axillary surgery (53.9% vs. 46.1%,  $p = 0.002$ ).

Patients with higher-grade tumors were more likely to undergo axillary surgery. Among those with grade 3 tumors, 58.9% had axillary procedures compared to 41.1% who did not ( $p < 0.001$ ). For grade 2 tumors, 45.1% underwent axillary surgery versus 54.9% who did not ( $p = 0.017$ ). In contrast, most patients with grade 1 tumors did not undergo axillary surgery (73.3% vs. 21.7%,  $p = 0.005$ ).

The presence of comedonecrosis was associated with a higher likelihood of axillary surgery, with 54.1% of patients undergoing axillary intervention compared to 38.0% of those without comedonecrosis ( $p = 0.004$ ).

Regarding diagnostic methods, patients diagnosed through mammography screening were more likely to avoid axillary surgery (52.4% vs. 47.6%,  $p = 0.009$ ). In contrast, those presenting with palpable lesions were

**Table 1** Clinical characteristics of the study cohort and comparison of patients with and without axillary surgery

Characteristics	Total n = 494		No Axillary Surgery n = 244		Axillary Surgery n = 250		p-value
	n	%	n	%	n	%	
<b>Age (years)</b>							
Mean [SD]	56.2 [10.7]		58.1 [10.8]		54.2 [10.7]		0.001
< 40 years	23	4.7	6	26.1	17	73.9	0.022
40–49 years	128	25.9	53	41.4	75	58.6	0.036
> ou = 50 years	343	69.4	185	53.9	158	46.1	0.002
<b>Nuclear Grade</b>							
G1	23	4.7	18	73.3	5	21.7	0.005
G2	235	47.6	129	54.9	106	45.1	0.017
G3	236	47.08	97	41.1	139	58.9	<0.001
<b>Comedonecrosis</b>							
Present	386	78.2	177	45.9	209	54.1	0.004
Absent	108	21.8	67	62.0	41	38.0	0.003
<b>Type of Diagnosis</b>							
Mamography Screening	391	79.1	205	52.4	186	47.6	0.009
Ultrasound	21	4.3	8	38.1	13	61.9	0.290
Palpable lesion	82	16.6	31	37.8	51	62.2	0.022
<b>Breast Surgery</b>							
Breast Conservative	359	72.7	233	64.9	126	35.1	<0.001
Mastectomy	113	22.9	11	8.1	124	91.9	<0.001
<b>Mamography Findings</b>							
Calcifications	361	73.1	190	52.6	171	47.4	0.014
Nodule	103	20.9	34	33.7	67	66.3	<0.001
Asymmetry	28	5.7	16	57.1	12	42.9	0.234
Architectural distortion	4	0.8	4	100.0	0	0%	0.001
<b>Invasive after surgery</b>							
No	475	96.2	242	50.9	233	49.1	<0.001
Yes	19	3.8	2	10.5	17	89.5	<0.001
<b>Immunohistochemistry</b>							
HR+ / HER-2 -	215	43.5	119	55.3	96	44.7	0.745
HR- / HER-2 -	42	8.5	22	52.4	20	47.6	0.592
HR- / HER-2 +	122	24.7	70	57.4	52	42.6	<0.001
HR+ / HER-2 +	115	23.3	33	28.7	82	71.3	<0.001

more likely to undergo axillary surgery (62.2% vs. 37.8%,  $p = 0.022$ ). For ultrasound-detected lesions, the difference was not statistically significant (65% vs. 38.1%,  $p = 0.290$ ).

Analysis of mammographic findings showed that calcifications were more common in the non-axillary surgery group (77.9% vs. 68.2%,  $p = 0.014$ ), while nodules were more prevalent in the axillary surgery group (26.9% vs. 13.9%,  $p < 0.001$ ). Architectural distortion was exclusively observed in the non-axillary surgery group (1.7% vs. 0%,  $p = 0.001$ ), whereas the difference in asymmetry was not statistically significant (6.5% vs. 4.9%,  $p = 0.234$ ).

A notable difference was found in breast surgery type. Among patients who underwent BCS, 64.9% did not have axillary surgery, compared to 35.1% who did ( $p < 0.001$ ). Conversely, among those who underwent mastectomy, the vast majority (91.9%) had axillary surgery, while only 8.1% did not.

Finally, postoperative upstaging to invasive carcinoma was significantly more frequent in the axillary surgery group than in the non-axillary surgery group (6.8% vs. 0.8%,  $p = 0.001$ ). Overall, upstaging to invasive carcinoma occurred in 3.8% of cases (19 out of 494), with only one instance in a patient younger than 40 years. These data are summarized in Table 1.

Two multivariate logistic regression models were constructed to identify factors independently associated with axillary surgical approach in patients with DCIS. The first model (Model A) included type of breast surgery as a predictor variable, while the second model (Model B) excluded this factor to isolate the influence of intrinsic patient and tumor characteristics.

In the first Model A, the most powerful predictor of axillary surgery was the type of breast procedure performed, with patients undergoing mastectomy being over 20 times more likely to have axillary evaluation compared

to those receiving BCS (OR = 20.22, 95% CI: 10.37–39.42,  $p < 0.001$ ). The presence of comedonecrosis also emerged as a significant predictor (OR = 1.90, 95% CI: 1.05–3.45,  $p = 0.034$ ), as did diagnosis by ultrasound compared to mammography (OR = 2.98, 95% CI: 1.10–8.04,  $p = 0.031$ ). Nuclear grade 3 tumors showed a marginally significant association with axillary surgery (OR = 3.41, 95% CI: 1.00–11.70,  $p = 0.051$ ), while younger age (< 40 years) demonstrated a similar trend (OR = 3.16, 95% CI: 0.96–10.37,  $p = 0.058$ ).

When the type of breast surgery was excluded from the analysis (Model B), additional factors emerged as significant independent predictors. Age became statistically significant, with patients younger than 40 years (OR = 3.08, 95% CI: 1.06–8.96,  $p = 0.039$ ) and those aged 40–49 years (OR = 1.64, 95% CI: 1.07–2.51,  $p = 0.022$ ) more likely to undergo axillary procedures compared to patients  $\geq 50$  years. Nuclear grade showed a stronger association, with grade 3 tumors having nearly five times the odds of axillary surgery compared to grade 1 tumors (OR = 4.95, 95% CI: 1.59–15.35,  $p = 0.006$ ). Grade 2 tumors also reached statistical significance (OR = 3.03, 95% CI: 1.00–9.18,  $p = 0.050$ ). The presence of comedonecrosis remained significant (OR = 1.78, 95% CI: 1.07–2.94,  $p = 0.026$ ), and presentation with a palpable lesion emerged as a new significant predictor (OR = 2.03, 95% CI: 1.16–3.56,  $p = 0.013$ ).

The goodness-of-fit statistics for both models revealed important differences in their predictive power. Both models demonstrated excellent calibration as indicated by the Hosmer-Lemeshow test ( $p = 0.865$  for Model A and  $p = 0.947$  for Model B), suggesting good agreement between observed and predicted values. However, the Nagelkerke  $R^2$  values differed substantially between the models: 39.0% for Model A versus only 10.7% for Model

B. This marked difference indicates that while the clinicopathological factors alone significantly influence axillary management decisions, they explain a relatively small proportion of the variance. In contrast, including the type of breast surgery substantially improved the model's explanatory power, suggesting that surgical approach to the breast is the predominant factor driving axillary management decisions in DCIS patients, with other factors playing a secondary though still significant role.

These findings demonstrate that while several intrinsic factors—including younger age, higher nuclear grade, presence of comedonecrosis, and symptomatic presentation—independently predict the likelihood of axillary surgery, the type of breast surgery remains the strongest determinant of axillary management in DCIS patients (Table 2).

To better elucidate factors associated with upstaging to invasive carcinoma, we performed a multivariate logistic regression analysis evaluating potential clinicopathologic predictors. Notably, none of the variables—including age, nuclear grade, comedonecrosis, or mode of presentation—were independently associated with upgrade to invasive carcinoma. These results are detailed in Table 3.

Among the 250 patients who underwent axillary surgery, 211 (84.4%) underwent SNB, while 39 (15.6%) underwent AD. Metastatic involvement of axillary lymph nodes was identified in only three patients (1.2% of all those who had axillary evaluation). All three had palpable lesions and were subsequently upstaged to invasive carcinoma on final pathology. Among them, one patient (0.4%) had undergone BCS, while two (0.8%) had mastectomies.

Notably, all three patients with positive lymph nodes were in the axillary dissection group, accounting for 7.9% of the AD cohort. No lymph node metastases were detected in any of the 211 patients who underwent

**Table 2** Multivariate logistic regression model for axillary surgery

Characteristics	Model A Breast Sugery			Model B Without Breast Sugery			
	OR	CI 95%	p-valor	OR	CI 95%	p-valor	
Age (years)	< 40 years	3.16	0.96–10.37	0.058	3.08	1.06–8.96	0.039
	40–49 years	1.35	0.82–2.21	0.234	1.64	1.07–2.51	0.022
	> ou = 50 years	Ref	-	-	-	-	-
Nuclear Grade	G1	Ref	-	-	-	-	-
	G2	2.02	0.61–6.77	0.252	3.03	1.00–9.18	0.050
	G3	3.41	1.00–11.70	0.051	4.95	1.59–15.35	0.006
Comedonecrosis	Ausent	Ref	-	-	-	-	-
	Present	1.90	1.05–3.45	0.034	1.78	1.07–2.94	0.026
Breast Surgery	BCS	Ref	-	-	-	-	-
	Mastectomy	20.22	10.37–39.42	< 0.001	-	-	-
Type of Diagnosis	Mamography	Ref	-	-	-	-	-
	Ultrasound	2.98	1.10–8.04	0.031	2.22	0.87–5.69	0.095
	Palpable lesion	1.69	0.89–3.24	0.111	2.03	1.16–3.56	0.013

Legend: OR – odds ratio; G – grade, Ref. – reference, BCS – breast conservative surgery, Mamography Screening

**Table 3** Multivariate logistic regression analysis of clinicopathologic predictors of upgrade to invasive carcinoma

Characteristics	Coefficient	SE	Z	CI 95%	p-value
Age					
Age < 40	0.11	1.12	0.10	2.08–2.31	0.921
Age ≥ 50	-0.03	0.54	-0.06	-1.08–1.02	0.953
Comedonecrosis					
Yes	-0.35	0.74	-0.48	-1.81–1.10	0.635
No	0.06	0.52	0.12	-0.96–1.10	0.906
Grade					
1	-3.20	0.46	-7.02	-4.10 – -2.31	< 0.001
2	0.11	1.12	0.10	-2.08–2.31	0.921
3	-0.03	0.54	-0.06	-1.08–1.02	0.953
Palpable					
Yes	-0.35	0.74	-0.48	-1.91–1.10	0.635
No	0.06	0.52	0.12	-0.96–1.09	0.906

sentinel node biopsy. This extremely low axillary metastasis rate (1.2%) in DCIS patients highlights the limited utility of routine axillary evaluation, particularly in the absence of clinical features suggestive of invasive disease (Fig. 2).

### Discussion

The widespread implementation of mammography screening has led to a significant increase in DCIS diagnoses. However, DCIS is a heterogeneous entity with varying malignant potential, making treatment decisions complex. Despite ongoing debates, the necessity of axillary evaluation in DCIS patients without invasive disease remains controversial. Currently, even in invasive disease, we face a dilemma. Recent studies suggest that routine axillary evaluation is unnecessary for early-stage tumors [13, 14].

In Brazil, the lack of an organized BC screening program within the public healthcare system presents challenges to early detection. The Ministry of Health recommends biennial mammographic screening for women aged 50 to 69 years [17]; however, multiple barriers hinder the widespread implementation of guidelines recommended by international medical societies, which advocate for screening to begin at age 40 [18]. Notably, breast cancer mortality rates among young women (30–39 years old) have increased across all regions of Brazil, highlighting the potential need to include this age group in screening initiatives [19].

In our analyses 79,1% of our cases were diagnosed with a mammography alterations, this is way different when compared to developed countries like the United States where 90% of cases are diagnosed by imaging [7].

Grade 1 and 2 tumors were identified in 4.7% and 47.7% of our cohort, respectively. These low- and intermediate-grade lesions are currently the focus of prospective trials evaluating the safety of non-surgical management strategies, such as the LORIS [20] LORD [21] and COMET [22]

studies. Recently, initial results from the COMET trial were published, supporting the feasibility of active surveillance in carefully selected low-risk DCIS patients [23]. The presence of comedonecrosis in the DCIS has been an exclusion criterion for trial enrolment in most studies, in our data comedonecrosis was present in 77,9% of our specimens but the concordance among experienced breast pathologists is highly variable as some authors have already shown [24].

DCIS is typically managed with surgical treatment, either through mastectomy or BCS. However, growing evidence suggests that aggressive surgical approaches may not be necessary to achieve long-term survival benefits in many cases [25, 26]. European guidelines from the ESMO group recommend that 60–80% of primary breast cancer patients should undergo BCS [27] which is consistent with our findings—72.7% of patients in our cohort were treated with breast-conserving surgery.

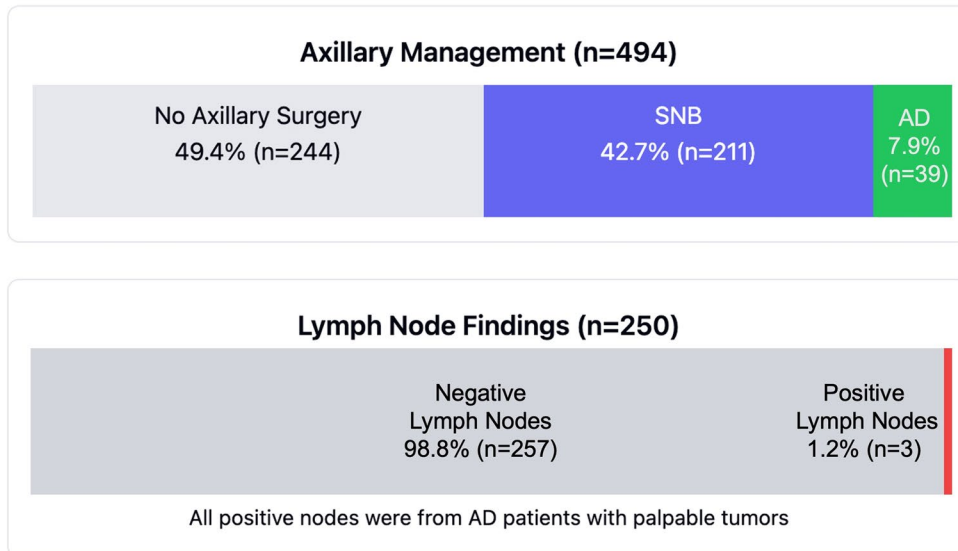
The majority of patients were aged 50 years or older (69.4%), while 30.6% were under 50. Notably, developing countries have reported a rising incidence of breast cancer in younger women [37].

DCIS is preinvasive and does not have the potential to spread to regional lymph nodes. Axillary dissection for DCIS, practiced in the 1980s, was gradually abandoned through the 1990s and further follow-up showed that its omission in patients with pure in situ disease had no adverse effect on survival or recurrence [12, 28].

The management of the axilla in DCIS has changed dramatically over the years [29]. The advent of SNB, with its low morbidity [30] prompted interest in its use in patients with DCIS who were considered to be at high risk of harboring an invasive component, such as those with adverse clinical or histological features (large, palpable tumors, mammographic mass, high grade).

Most patients with DCIS and lymph node metastases probably harbored an unrecognized focus of invasion in the breast or had metastases subsequent to an


### Key Findings from DCIS Axillary Management Study



### Multivariate Analysis: Odds Ratios and p-values for Axillary Surgery

Factor	Model A (with surgery type)		Model B (without surgery type)	
	OR	p-value	OR	p-value
Age <40 years	3.16	0.058	<b>3.08</b>	<b>0.039</b>
Age 40-49 years	1.35	0.234	<b>1.64</b>	<b>0.022</b>
Grade 2	2.02	0.252	<b>3.03</b>	<b>0.050</b>
Grade 3	<b>3.41</b>	<b>0.051</b>	<b>4.95</b>	<b>0.006</b>
Comedonecrosis	<b>1.90</b>	<b>0.034</b>	<b>1.78</b>	<b>0.026</b>
Mastectomy	<b>20.22</b>	<b>&lt;0.001</b>	—	—
Ultrasound	<b>2.98</b>	<b>0.031</b>	2.22	0.095
Palpable lesion	1.69	0.111	<b>2.03</b>	<b>0.013</b>

### Model Explanatory Power



Nagelkerke R<sup>2</sup> value comparison shows the dominant influence of breast surgery type

**Fig. 2** Axillary Management in DCIS: Distribution, Lymph Node Outcomes, and Multivariate Analysis of Predictive Factors

invasive local recurrence [31]. As a result, some authors recommended that SNB biopsy should be performed in all patients with a preoperative core biopsy diagnosis of DCIS. However, subsequent studies found a lower rate of nodal involvement which discouraged routine SNB biopsy [32–34] but to the date there has been no prospective randomized trial to address the value of SNB biopsy in patients with DCIS.

In most studies a palpable mass, a mammographic mass, a high-grade lesion and a large size were associated with a significant risk of invasive disease in the final resection specimen [35]. However, there were inconsistencies and so a more robust prediction model is desirable. Advocates of SNB in DCIS at the time of excision suggest that this technique may not be reliable after tumor excision and that patients should undergo an axillary lymph node dissection if a SNB was not performed at the time of the first operation [36] but there is a possibility in performing SNB as a second procedure after lumpectomy [37–40]. After mastectomy or wide quadrantectomy of the upper outer quadrant, it is challenging, and in such situations, most authors recommend concomitant SNB [41] it has also been advocated in high-risk patients with DCIS [42].

In all cases, SNB was performed using blue dye alone, as access to radioguided technetium-99 m is limited in many Brazilian public hospitals, including our institution. This constraint may partially explain the higher-than-expected rate of axillary dissections in our cohort (7.9%), as some patients underwent axillary dissection due to failed SNB mapping or intraoperative uncertainty regarding nodal status. While blue dye-only SNB remains a feasible technique in resource-constrained settings, its lower detection rate compared to dual-tracer methods is a known limitation.

In our cohort, upstaging to invasive carcinoma was observed in only 3.8% of cases, with just one instance occurring in a patient younger than 40 years. Among the upstaged cases, only two patients (0.4%) had positive lymph nodes, none with more than two involved nodes. These findings reinforce the notion that axillary staging in DCIS provides limited prognostic or therapeutic value while exposing patients to unnecessary surgical morbidity. The relatively low upstaging rate observed in our study, compared to other series [4] may be attributed to our institution's routine practice of performing vacuum-assisted biopsy for most mammography-detected lesions, which may enhance diagnostic accuracy and reduce false-negative rates. It is also well established that the absolute and relative risks of detecting a positive SNB in DCIS are 5% and 1%, respectively [4].

Currently, preoperative axillary ultrasound plays an increasingly important role in selecting candidates for SNB in early-stage invasive breast cancer, enabling

targeted biopsies in cases with suspicious nodal features. Although SNB is associated with minimal morbidity, complications such as lymphedema and sensory nerve injury persist in 10–15% of cases, significantly affecting quality of life. The majority of patients undergoing SNB for DCIS derive no substantial clinical benefit from the procedure, yet they are subjected to increased postoperative complications and unnecessary healthcare costs. These findings indicate that the role of SNB in DCIS warrants further scrutiny, particularly in patients without clinical or radiological suspicion of invasion [43, 44].

Throughout the past twenty years, the medical community has shown growing concern regarding the reduction of unnecessary interventions for patients diagnosed with DCIS, evidenced by ongoing clinical trials comparing observation protocols versus surgical treatments for low-risk DCIS cases [45]. Concurrently, there exists considerable momentum toward minimizing the use of SNB procedures [46] This shift stems primarily from the demonstrated minimal utility of SNB in DCIS patients. Historical data from the NSABP B-17 and B-24 trials, conducted prior to SNB implementation, revealed minimal rates of nodal recurrence following lumpectomy for DCIS, with merely 0.38% developing ipsilateral nodal recurrence during extended follow-up periods [46] Correspondingly, a contemporary meta-analysis encompassing 9,803 individuals who underwent either mastectomy or BCS identified only a 3.7% SNB-positivity rate in DCIS cases [10] Yet, despite these consistently low positivity findings, established literature continues to highlight significant potential complications following axillary surgical interventions [46].

Contrary to these evidence-based insights, SNB implementation in DCIS management continues to rise. A comprehensive National Cancer Database examination involving 178,762 DCIS patients revealed axillary surgical procedures occurred in 19% of individuals receiving BCS (contradicting established National Comprehensive Cancer Network guidelines), while among mastectomy recipients, axillary surgery rates increased from 86% in 2012 to 90% by 2018<sup>11</sup>. Additionally, a recent professional practice survey examining axillary staging methodologies among surgeons found that one-third continued to advocate for SNB in BCS patients, while more than 80% recommended this procedure for patients undergoing mastectomy [47].

An important factor when considering de-escalation of axillary surgery is the potential for underestimation of invasive disease at the time of VAB. Previous studies have shown that the rate of underestimation—defined as the presence of invasive carcinoma in the surgical specimen after a core or VAB diagnosis of pure DCIS—ranges from 5 to 25%, depending on lesion size, histological grade, imaging features, and biopsy technique [8]. However,

the use of VAB with larger gauge needles and multiple sampling passes significantly reduces the risk of missing invasive foci compared to traditional core needle biopsies. Importantly, when the procedure achieves complete removal of microcalcifications, and the lesion is small, the underestimation rate is even lower. In our cohort, the upstaging rate to invasive carcinoma was only 3.8%, which is lower than most reported series. This likely reflects the routine use of VAB in our institution for suspicious calcifications and non-palpable lesions, enhancing diagnostic accuracy and decreasing false-negative results. Therefore, in well-selected patients diagnosed with DCIS by VAB, particularly when complete calcification removal is achieved and the lesion is small, the risk of nodal involvement is exceedingly low—further supporting the omission of sentinel lymph node biopsy in this context [9].

For DCIS patients, SNB should be reserved exclusively for individuals at highest risk for upstaging to invasive carcinoma. Nevertheless, presently there exists no standardized protocol for identifying appropriate candidates. Clinically validated risk assessment tools have been developed to assist practitioners in evaluating upstaging probability, thereby facilitating informed decisions regarding which patients require axillary staging versus those who can safely forego this procedure. These assessment instruments incorporate numerous variables including mass presence, disease multifocality, histological grade, mammographic calcification extent, and additional relevant factors [48].

One of the primary objectives of our study was to evaluate whether axillary surgery could be entirely omitted in DCIS patients. Our findings strongly support this hypothesis, as no patients with pure DCIS exhibited axillary lymph node involvement. This suggests that routine axillary surgery, whether SNB or axillary dissection, may not be justified in this population. Notably, even among cases that were upstaged to invasive carcinoma, lymph node involvement was exceedingly rare and did not exceed two positive nodes, further reinforcing the argument against aggressive axillary intervention in DCIS cases.

Our study has limitations inherent to its retrospective design, including potential selection bias and missing data. Additionally, the relatively small number of patients in certain subgroups may limit statistical power. We did not assess cost-effectiveness or long-term morbidity associated with different axillary surgical approaches—factors that warrant further investigation. Nonetheless, our findings contribute valuable real-world data supporting the reconsideration of routine SNB in DCIS patients.

## Conclusion

Our findings strongly suggest that routine axillary surgery in DCIS diagnosed by vacuum-assisted biopsy does not appear to be routinely necessary. The absence of axillary lymph node involvement in pure DCIS cases supports de-escalating axillary intervention to minimize unnecessary surgical morbidity. Future prospective studies should refine selection criteria to better identify patients who may benefit from axillary surgery.

## Acknowledgements

We thank all the patients included in the trial.

## Author contributions

Marcellus do Nascimento Moreira Ramos: Data curation, Formal analysis, Investigation, Writing – review & editing; André Mattar: Conceptualization, Methodology, Project administration, Supervision, Writing – review & editing; Marcelo Antonini: Project administration, Supervision, Writing – review & editing; Felipe Zerwes: Writing – review & editing; Felipe Cavagna: Data curation, Writing – review & editing; Francisco Pimentel Cavalcante: Writing – review & editing; Eduardo Camargo Millen: Writing – review & editing; Fabricio Palermo Brenelli: Writing – review & editing; Antonio Luiz Frasson: Writing – review & editing; Marcelo Madeira: Writing – review & editing; Marina Diógenes Teixeira: Writing – review & editing; Andressa Gonçalves Amorim: Data curation, Writing – review & editing; Marina Fleury de Figueiredo: Writing – review & editing; Larissa Chrispim de Oliveira: Writing – review & editing; Leonardo Ribeiro Sorares: Writing – review & editing; Gil Facina: Writing – review & editing; Rogerio Fenile: Writing – review & editing; Ruffo de Freitas Júnior: Writing – review & editing; Renata Arakelian: Writing – review & editing; Marcela Bonalumi dos Santos: Writing – review & editing; Henrique Lima Couto: Writing – review & editing; Renata Montarroyos Leite: Writing – review & editing; Pedro Paulo de Andrade Gomes: Writing – review & editing; Gabriela de Oliveira Gomes: Writing – review & editing; Luiz Henrique Gebrim: Writing – review & editing; Reginaldo Guedes Coelho Lopes: Supervision, Writing – review & editing; Juliana Monte Real: Supervision, Writing – review & editing.

## Funding

None.

## Data availability

All data is available upon request. Contact mattar.andre@gmail.com.

## Declarations

### Ethical approval

was obtained from Institutional Review Board at Perola Byington Hospital, São Paulo, Brazil under the number CAEE 72387317.6.0000.0069 and the inform consent was dismissed.

### Competing interests

The authors declare no competing interests.

### Disclosures

None of the authors have disclosures for this article.

### Author details

<sup>1</sup>Hospital do Servidor Público Estadual Francisco Morato de Oliveira, São Paulo, Brazil

<sup>2</sup>Centro de Referência da Saúde da Mulher – Hospital da Mulher, São Paulo, Brazil

<sup>3</sup>BBREAST Group: Brazilian Breast Cancer Associate Research Team, São Paulo, Brazil

<sup>4</sup>Pontifícia Universidade Católica do Rio Grande do Sul (PUCRS), Porto Alegre, Rio Grande do Sul, Brazil

<sup>5</sup>Oncoclínicas, Porto Alegre, Rio Grande do Sul, Brazil

<sup>6</sup>Hospital Geral de Fortaleza, Fortaleza, Ceará, Brazil

<sup>7</sup>Américas Oncologia, Rio de Janeiro, Brazil

<sup>8</sup>Universidade Estadual de Campinas (UNICAMP), Campinas, São Paulo, Brazil

<sup>9</sup>Hospital Albert Einstein, São Paulo, Brazil

<sup>10</sup>Faculdade Israelita de Ciências da Saúde Albert Einstein, São Paulo, Brazil

<sup>11</sup>Universidade Federal de Goiás, Goiânia, GO, Brazil

<sup>12</sup>Universidade Federal de São Paulo, São Paulo, Brazil

<sup>13</sup>Hospital Ipiranga, São Paulo, Brazil

<sup>14</sup>CORA Advanced Center for Breast Cancer Diagnosis, Federal University of Goiás, Goiânia, Goiás, Brazil

<sup>15</sup>DASA Oncologia, São Paulo, Brazil

<sup>16</sup>Oncoclínicas, São Paulo, Brazil

<sup>17</sup>Redimama - Redimasto, Belo Horizonte, Minas Gerais, Brazil

<sup>18</sup>Oncoclínicas, Aracaju, Sergipe, Brazil

<sup>19</sup>Universidade Federal de Sergipe, Aracaju, Sergipe, Brazil

<sup>20</sup>Hospital Beneficência Portuguesa de São Paulo, São Paulo, Brazil

Received: 21 May 2025 / Accepted: 28 June 2025

Published online: 12 July 2025

## References

- Bane A. Ductal carcinoma in situ: what the pathologist needs to know and why. *Int J Breast Cancer*. 2013; 2013: 914053.
- Ramzi S, Najeib E, Coulthard J, et al. Does Sentinel lymph node biopsy for screening high-grade ductal carcinoma in situ of the breast cause more harm than good? *Breast Cancer Res Treat*. 2020;182(1):47–54.
- Mittendorf EA, Arciero CA, Gutchell V, et al. Core biopsy diagnosis of ductal carcinoma in situ: an indication for Sentinel lymph node biopsy. *Curr Surg*. 2005;62(2):253–7.
- Davey MG, O'Flaherty C, Cleere EF et al. Sentinel lymph node biopsy in patients with ductal carcinoma in situ: systematic review and meta-analysis. *BJS Open* 2022; 6 (2).
- Netter E, Troufléau P, Stinès J. [Ductal carcinoma in situ of the breast: role of imaging]. *J Radiol*. 1998;79(7):651–8.
- DeSantis C, Siegel R, Bandi P, et al. Breast cancer statistics, 2011. *CA Cancer J Clin*. 2011;61(6):409–18.
- Siegel RL, Miller KD, Jemal A, Cancer statistics. 2018. *CA Cancer J Clin* 2018; 68 (1): 7–30.
- Cullinane C, Byrne J, Kelly L, et al. The positive predictive value of vacuum assisted biopsy (VAB) in predicting final histological diagnosis for breast lesions of uncertain malignancy (B3 lesions): A systematic review & meta-analysis. *Eur J Surg Oncol*. 2022;48(7):1464–74.
- Sanderink WBG, Laarhuis BI, Strobbe LJA, et al. A systematic review on the use of the breast lesion excision system in breast disease. *Insights Imaging*. 2019;10(1):49.
- El Hage Chehade H, Headon H, Wazir U, et al. Is Sentinel lymph node biopsy indicated in patients with a diagnosis of ductal carcinoma in situ? A systematic literature review and meta-analysis. *Am J Surg*. 2017;213(1):171–80.
- Piltin MA, Hoskin TL, Day CN, et al. Overuse of axillary surgery in patients with ductal carcinoma in situ: opportunity for De-escalation. *Ann Surg Oncol*. 2022;29(12):7705–12.
- Killelea BK, Long JB, Dang W, et al. Associations between Sentinel lymph node biopsy and complications for patients with ductal carcinoma in situ. *Ann Surg Oncol*. 2018;25(6):1521–9.
- Gentilini OD, Botteri E, Sangalli C, et al. Sentinel lymph node biopsy vs no axillary surgery in patients with small breast Cancer and negative results on ultrasonography of axillary lymph nodes: the SOUND randomized clinical trial. *JAMA Oncol*. 2023;9(11):1557–64.
- Reimer T, Stachs A, Veselinovic K et al. Axillary surgery in breast Cancer - Primary results of the INSEMA trial. *N Engl J Med* 2024.
- Motheral B, Brooks J, Clark MA, et al. A checklist for retrospective database studies—report of the ISPOR task force on retrospective databases. *Value Health*. 2003;6(2):90–7.
- Network NCC. Breast Cancer (Version 2.2024). 2024.
- Viacava F, Ugá MA, Porto S, et al. [Evaluation of performance of health systems: a model for analysis]. *Cien Saude Colet*. 2012;17(4):921–34.
- Rodrigues DCN, Freitas-Junior R, Rahal RMS, et al. Difficult access and poor productivity: mammography screening in Brazil. *Asian Pac J Cancer Prev*. 2019;20(6):1857–64.
- Silva JDDE, de Oliveira RR, da Silva MT et al. Breast Cancer mortality in young women in Brazil. *Front Oncol* 2021; 10.
- Wheelwright S, Matthews L, Jenkins V, et al. Recruiting women with ductal carcinoma in situ to a randomised controlled trial: lessons from the LORIS study. *Trials*. 2023;24(1):670.
- Schmitz RSJM, Engelhardt EG, Gerritsma MA et al. Active surveillance versus treatment in low-risk DCIS: Women's preferences in the LORD-trial. *European Journal of Cancer* 2023; 192.
- Hwang ES, Hyslop T, Lynch T, et al. The COMET (Comparison of operative versus monitoring and endocrine Therapy) trial: a phase III randomised controlled clinical trial for low-risk ductal carcinoma in situ (DCIS). *BMJ Open*. 2019;9(3):e026797.
- Hwang ES, Hyslop T, Lynch T, et al. Active monitoring with or without endocrine therapy for Low-Risk ductal carcinoma in situ: the COMET randomized clinical trial. *JAMA*. 2025;333(11):972–80.
- Harrison BT, Hwang ES, Partridge AH, et al. Variability in diagnostic threshold for comedo necrosis among breast pathologists: implications for patient eligibility for active surveillance trials of ductal carcinoma in situ. *Mod Pathol*. 2019;32(9):1257–62.
- Worni M, Akushevich I, Greenup R, et al. Trends in treatment patterns and outcomes for ductal carcinoma in situ. *J Natl Cancer Inst*. 2015;107(12):djv263.
- Narod SA, Iqbal J, Giannakeas V, et al. Breast Cancer mortality after a diagnosis of ductal carcinoma in situ. *JAMA Oncol*. 2015;1(7):888–96.
- Senkus E, Kyriakides S, Ohno S, et al. Primary breast cancer: ESMO clinical practice guidelines for diagnosis, treatment and follow-up. *Ann Oncol*. 2015;26(Suppl 5):v8–30.
- Wadsten C, Garmo H, Fredriksson I, et al. Risk of death from breast cancer after treatment for ductal carcinoma in situ. *Br J Surg*. 2017;104(11):1506–13.
- Baxter NN, Virnig BA, Durham SB, et al. Trends in the treatment of ductal carcinoma in situ of the breast. *J Natl Cancer Inst*. 2004;96(6):443–8.
- Mansel RE, Fallowfield L, Kissin M, et al. Randomized multicenter trial of Sentinel node biopsy versus standard axillary treatment in operable breast cancer: the ALMANAC trial. *J Natl Cancer Inst*. 2006;98(9):599–609.
- Silverstein MJ, Skinner KA, Lomis TJ. Predicting axillary nodal positivity in 2282 patients with breast carcinoma. *World J Surg*. 2001;25(6):767–72.
- Kelly TA, Kim JA, Patrick R, et al. Axillary lymph node metastases in patients with a final diagnosis of ductal carcinoma in situ. *Am J Surg*. 2003;186(4):368–70.
- Intra M, Veronesi P, Mazzaro G, et al. Axillary Sentinel lymph node biopsy in patients with pure ductal carcinoma in situ of the breast. *Arch Surg*. 2003;138(3):309–13.
- Brennan ME, Turner RM, Ciatto S, et al. Ductal carcinoma in situ at core-needle biopsy: meta-analysis of underestimation and predictors of invasive breast cancer. *Radiology*. 2011;260(1):119–28.
- Ansari B, Ogston SA, Purdie CA, et al. Meta-analysis of Sentinel node biopsy in ductal carcinoma in situ of the breast. *Br J Surg*. 2008;95(5):547–54.
- Cox CE, Nguyen K, Gray RJ et al. Importance of lymphatic mapping in ductal carcinoma in situ (DCIS): why map DCIS? *Am Surg*. 2001; 67 (6): 513–519; discussion 519–521.
- Wong SL, Edwards MJ, Chao C, et al. The effect of prior breast biopsy method and concurrent definitive breast procedure on success and accuracy of Sentinel lymph node biopsy. *Ann Surg Oncol*. 2002;9(3):272–7.
- Luini A, Galimberti V, Gatti G, et al. The Sentinel node biopsy after previous breast surgery: preliminary results on 543 patients treated at the European Institute of oncology. *Breast Cancer Res Treat*. 2005;89(2):159–63.
- Martin TA, Choudhry S, Holton LH, et al. Is Sentinel lymph node biopsy reliable after recent oncoplastic breast reduction?? *Am Surg*. 2023;89(5):2056–8.
- Renaudeau C, Lefebvre-Lacoeuille C, Campion L, et al. Evaluation of Sentinel lymph node biopsy after previous breast surgery for breast cancer: GATA study. *Breast*. 2016;28:54–9.
- Zavagno G, Carcoforo P, Marconato R, et al. Role of axillary Sentinel lymph node biopsy in patients with pure ductal carcinoma in situ of the breast. *BMC Cancer*. 2005;5(1):28.
- Cody HS 3rd, Van Zee KJ. Point: Sentinel lymph node biopsy is indicated for patients with DCIS. *J Natl Compr Canc Netw*. 2003;1(2):199–206.
- Zhang K, Qian L, Zhu Q, et al. Prediction of Sentinel lymph node metastasis in breast ductal carcinoma in situ diagnosed by preoperative core needle biopsy. *Front Oncol*. 2020;10:590686.
- James TA, Palis B, McCabe R, et al. Evaluating the role of Sentinel lymph node biopsy in patients with DCIS treated with breast conserving surgery. *Am J Surg*. 2020;220(3):654–9.

45. Iwamoto N, Nara M, Horiguchi SI, et al. Surgical upstaging rates in patients meeting the eligibility for active surveillance trials. *Jpn J Clin Oncol.* 2021;51(8):1219–24.
46. Ayub A, Senol K, Eleftherios M, et al. De-Escalating the extent of Sentinel lymph node biopsy in patients with ductal carcinoma in situ undergoing mastectomy. *Clin Breast Cancer.* 2024;24(8):716–20.
47. Armani A, Douglas S, Kulkarni S, et al. Controversial areas in axillary staging: are we following the guidelines?? *Ann Surg Oncol.* 2021;28(10):5580–7.
48. Jakub JW, Murphy BL, Gonzalez AB, et al. A validated nomogram to predict upstaging of ductal carcinoma in situ to invasive disease. *Ann Surg Oncol.* 2017;24(10):2915–24.

#### **Publisher's note**

Springer Nature remains neutral with regard to jurisdictional claims in published maps and institutional affiliations.