

Positive Identification of Skeletal Remains Combining Smile Photographs and Forensic Anthropology – A Case Report

Rhonan Ferreira Silva^{1,2}, Ademir Franco³, Fernando Fortes Picoli^{1,2}, Livia Grazielle Rodrigues², Rhodolfo Ferreira Silva^{4,1} and João Batista de Souza²

¹Forensic Odontology, Scientific Police, State of Goiás, Brazil

²Postgraduate Program in Dentistry, Federal University of Goiás, Brazil

³Forensic Odontology, Katholieke Universiteit Leuven, Belgium

⁴Dentistry, Paulista University, State of Goiás, Brazil

*Corresponding author: Rhonan Ferreira Silva, Forensic Odontology, Federal University of Goiás, Av. Universitaria, Esquina com 1 Avenida s/n, Setor Universitario, Postal code: 74605-220, Goiania, Goiás, Brazil, Tel: 00-55-62-3209-6051; E-mail: rhonans@terra.com.br

Rec date: April 07, 2015 Acc date: June 27, 2015 Pub date: August 02, 2015

Copyright: © 2015 Silva RF, et al. This is an open-access article distributed under the terms of the Creative Commons Attribution License, which permits unrestricted use, distribution, and reproduction in any medium, provided the original author and source are credited.

Abstract

Forensic experts may face challenging situations in the routine of human identifications, such as the lack of ante-mortem (AM) data; and cadaveric alterations, such as charred, mutilated and decomposed bodies, as well as skeletal remains. In this context, alternative pathways for human identification must be taken following scientific criteria. The present study reports a case of human identification combining the analysis of smile photographs and forensic anthropology exams. Skeletal remains of were referred for human identification in the local medico-legal institute. The anthropological profile of the victim, containing age, sex, stature and ancestry information pointed out a potential victim from a police list of missing persons. Relatives of the victims did not provide AM data; except for a single smile photograph from the victim's personal belongings. Dental autopsy, previously guided by anthropological exams, culminated in positive identification. Similar to all the other pathways for human identification, the analysis of smile photographs presents advantages and limitations. However, when combined to other methods, such as forensic anthropology, smile photographs trend the reveal greater application.

Keywords: Forensic odontology; Human identification; Smile; Photographs; Forensic anthropology

separately or combined with additional methods for human identification.

Introduction

The increasing trend of violent deaths in the last decades consequently raised the number of bodies undergoing cadaveric examination worldwide, especially in Brazil [1]. From a forensic scope, violent deaths are closely related with cadaveric alterations. In this context, forensic experts may find charred [2], mutilated [3], and decomposed bodies [4], as well as skeletal remains [5]. These alterations consist of special situations, in which the human identification process is potentially hampered. Specifically, soft tissues are not often preserved, lacking fingerprint and facial analyses. Based on that, forensic dentistry arises as an alternative for reliable human identification founded on the analysis of hard tissues [6].

On the other hand, traditional dental human identifications are performed on a comparative basis, in which anatomic, therapeutic, and pathological dental identifiers found in post-mortem (PM) data are matched with dental identifiers registered ante-mortem (AM) [7]. The medical literature describes several pathways for the registration of AM data, such as dental files, dental radiographs, computed tomography, dental casts, and smile photographs [7]. In specific, smile photographs became more common in the medico-legal institutes over the time following the current increase of digital inclusion, social networking, and virtual communication.

Based on that, the present study aims to report a case of dental identification of human skeletal remains through the analysis of smile photographs, highlighting the relevance of approaching the technique

Case Report

Skeletal remains were found near to the countryside of Goiás, Midwest Brazil. After crime scene investigation, the remains underwent cadaveric examination in the local medico-legal institute for human identification and determination of the cause of death.

Once cleaned and anatomically positioned, the human bones revealed unclosed cranial sutures; unfused epiphysis of radius, ulna, humerus, femur, fibula, and tibia; vertebrae with fused rings without osteophytes; and clavicle epiphysis in final stage of fusion, indicating a victim aged between 18 and 25 years old according to Mckern and Stewart [8].

Additionally, the analysis of cranial and pelvic anatomic patterns indicated a male victim according to White and Folkens [9]. According to the same authors [9], the cranial traits revealed both Negroid and Caucasoid ancestry. Yet the analysis of long bones pointed out the approximate height between 169cm e 177cm according to Dupertuis and Hadden [10].

The dental autopsy revealed empty sockets in the region of maxillary right lateral incisor (#12), mandibular left central incisor (#31) and mandibular right central incisor (#41), suggesting PM missing teeth.

Amalgam fillings were detected in the maxillary right (#16) and left (#26) first molars, as well as in the mandibular left first (#36) and second (#37) molars. Third molars were fully erupted and developed,

and mandibular canines (#33 and #43) and lateral incisors (#32 and #42) were crowded (Figure 1).

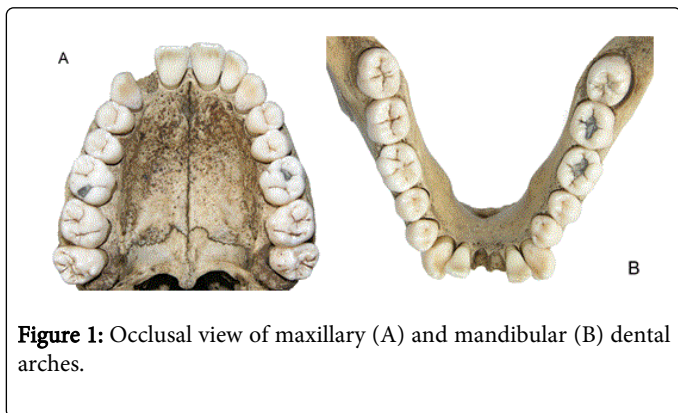


Figure 1: Occlusal view of maxillary (A) and mandibular (B) dental arches.

The medical autopsy associated the cause of death with firearm patterned injuries in the mandible (Figure 2), cervical vertebrae (C1 and C2), pelvic bones and ribs.

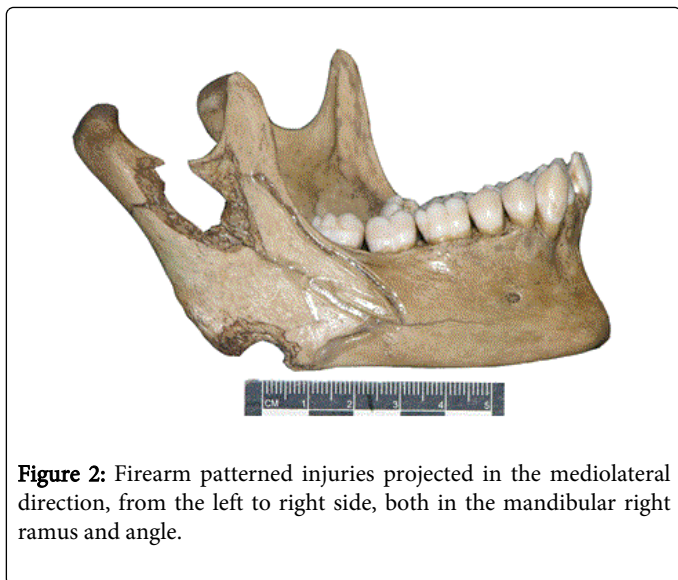


Figure 2: Firearm patterned injuries projected in the mediolateral direction, from the left to right side, both in the mandibular right ramus and angle.

Police investigations indicated a potential victim, missing for 42 days. The police records veiled that the missing person was an 18-years-old male of hybrid ancestry, measuring 173cm of height.

Relatives of the potential victim were requested to provide any medical, dental or personal data containing unique anatomic, radiographic and pathological characteristics. A smile photograph, dated from one year before the missing report, was provided becoming AM data.

The AM smile photograph enabled the visualization of crowding between mandibular canines and lateral incisors and the shape and position of the maxillary anterior teeth, previously observed PM.

Maxilla and mandible were collected from the skeletal remains, articulated and photographed approximately in the same position observed AM in order to allow a qualitative comparison (Figure 3).

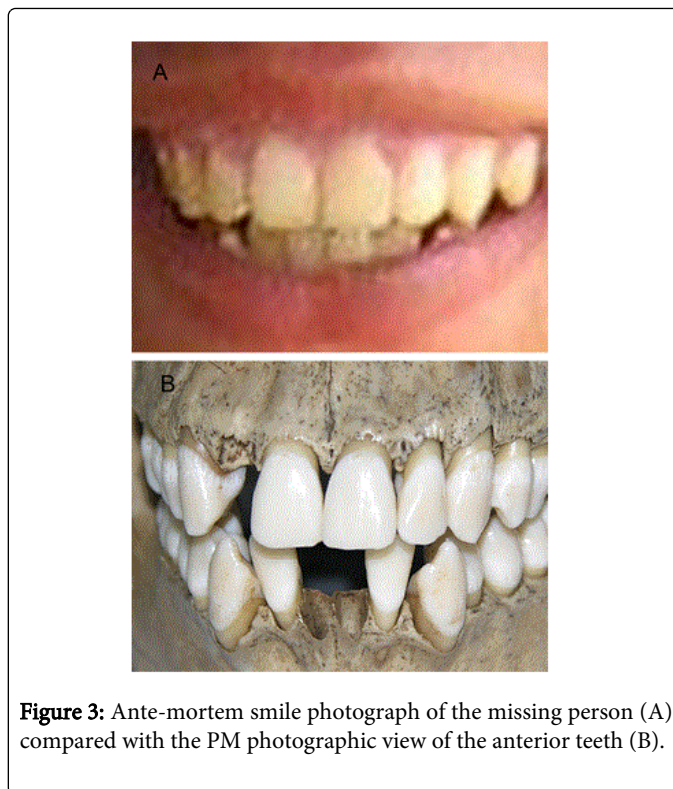


Figure 3: Ante-mortem smile photograph of the missing person (A) compared with the PM photographic view of the anterior teeth (B).

After reaching ideal vertical and horizontal angle adjustment, the images were imported into Adobe Photoshop® CS5 (Adobe Systems®, San Jose, CA, USA) software for imaging manipulation. Both images were cropped and superimposed, without modifying size proportions, using transparency/opacity tool levels at 50%. Only the PM teeth remained 100% transparent over the AM mouth (Figure 4).

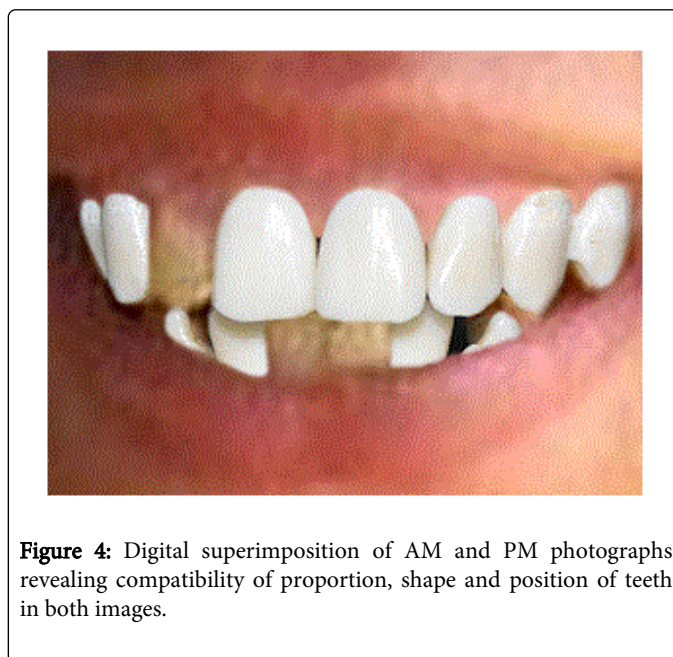


Figure 4: Digital superimposition of AM and PM photographs revealing compatibility of proportion, shape and position of teeth in both images.

Both in the direct comparison, as well as in the digital superimposition, AM and PM images revealed high compatibility of proportion, shape and position of teeth in the maxillary and

mandibular dental arches. In specific, dental crowding between mandibular canines and lateral incisors consisted of the most evident identifier. The association between the dental exam and the anthropological findings detected during the cadaveric examination successfully directed to a positive human identification.

Discussion

The increasing trend of digital inclusion expanded virtual networking and communication, making people more familiar with photographic devices, such as câmeras and smartphones [11]. Consequently, casual smile photographs became produced in large scale and stored all over the internet. Specifically, smile photographs register the anterior dentition recording the shape, position, angulation, size, color, incisal alignment and occlusal relation of maxillary and mandibular incisor and canines. In special situations smile photographs with open mouth may also record other identifiers, such as dental restorations and prosthetic appliances. In this context, these photographs represent a valuable source of AM data, and an alternative method for human identification, in the absence of medical and dental records [12].

In the forensic environment, smile photographs were tested according to its reliability simulating a comparative dental identification. Patients not treated orthodontically were correctly identified in 91.6% of the cases, while orthodontically treated patients were identified in 72.9% of the cases [13]. Clearly, patients without orthodontic treatment tend to present a higher prevalence of misaligned teeth and crowding. In the present case, crowding was the most evident dental identifier for comparative human identification. Accordingly, other authors also reported dental human identification through smile photographs mainly founded in crowding of the anterior dentition [12,14].

Despite valuable for specific cases of human identification, smile photographs must be approached only after searching and analyzing all the available medical and dental records [12], because as personal belonging smile photographs do not have the same technical standard found in radiographs and computed tomography. In the present study, smile photographs were only assessed after detailed anthropological exam. In fact, the creation of an anthropological profile of the victim was useful for reducing police lists of missing persons, pointing out a single potential victim.

After guided by the anthropological exam, the search for a potential victim was benefited by two advantages found in the analysis of smile photographs: the quick image enhancement, and the possibility of PM simulated reproduction. Both photographic enhancement and PM simulation of the AM photograph were performed in the present study aiming optimal outcomes. In this context, image manipulation software must be used allowing metric and superimposition approaches. However, size proportions of the AM and PM photographs must remain unaltered, enabling a reliable comparison. Otherwise, the images can be freely manipulated to fit each other, masking potential mismatches.

Conclusion

Smile photographs emerge as valuable alternative source of AM data in the forensic environment. Despite limitations, such as the lack of technical standard found in personal photographs, the use of smile register may be potentially combined with other forensic exams, such as the reconstruction of an anthropological profile of the victim for better outcomes. The present study illustrates a positive identification through smile photograph analysis and supports further researches on the field.

References

1. Minayo MCS (2009) Six characteristics of violent deaths in Brazil. *Rev Bras Estud Popul* 26: 135-140.
2. Silva RF, Oliveira CFP, Souza POC, Rodrigues LG, Mundim MBV, et al. (2015) Forensic outcomes of misfiled dental records “ case report. *Braz J Forensic Sci Med Law Bioethics* 4: 209-217.
3. Silva RF, De la Cruz BVM, Daruge Jr E, Daruge E, Franceschini Jr LF (2005) The importance of dental documentation in human identification: report of a case. *Acta Odontol Venez* 43: e1.
4. Quatrehomme G, Biglia E, Padovani B, du Jardin P, Alunni V (2014) Positive identification by X-rays bone trabeculae comparison. *Forensic Sci Int* 245C: e11-11e14.
5. Carneiro JL, Santos A, Magalhães T, Afonso A, Caldas IM (2015) Human identification using dental techniques: A case report. *Med Sci Law* 55: 78-81.
6. Silva RF, Franco A, Dias PEM, GonÁalves AS, Paranhos LR (2013) Interrelationship between forensic radiology and forensic odontology “ a case report of identified skeletal remains. *J Forensic Radiol Imag* 1: 201-206.
7. Senn DR, Weems RA (2013) *Manual of forensic odontology* (5th edn) Taylor & Francis CRC Press.
8. McKern TW, Stewart TD (1957) Skeletal age changes in young American males: analyzed from the standpoint of age identification (1stedn). *Quartermaster Research & Development Center*.
9. White TD, Folkens PA (2005) *The human bone manual* (1stedn) Academic Press.
10. Dupertuis CW, Hadden JA Jr (1951) On the reconstruction of stature from long bones. *Am J Phys Anthropol* 9: 15-53.
11. Assuno RS, Matos PM (2014) Perspective of adolescents about Facebook use: a qualitative study. *Psicol Estud* 19: 539-547.
12. Tinoco RL, Martins EC, Daruge E Jr, Daruge E, Prado FB, et al. (2010) Dental anomalies and their value in human identification: a case report. *J Forensic Odontostomatol* 28: 39-43.
13. Silva RF, Lima LNC, Martorell LB, Prado MM, Franceschini Jr L, et al. (2012) Comparative study among dentistry undergraduates and forensic odontology postgraduate students through smile photographs for human identification. *RSBO* 9: 407-415.
14. Terada ASSD, Leite NLP, Silveira TCP, Secchieri JM, GuimarÃes MA, et al. (2011) Human identification in forensic dentistry from a photographic record of smile: a case report. *Rev Odontol UNESP* 40: 199-202.