

## Mortality of *Cebus apella* by *Molineus torulosus* Parasitism in Midwestern Brazil

Marina Pacheco Miguel<sup>1</sup>, Sabrina Castilho Duarte<sup>2</sup>, Adriana Silva Santos<sup>2</sup>,  
Moema Pacheco Chediak Matos<sup>2</sup> & Marcos de Almeida Souza<sup>3</sup>

### ABSTRACT

**Background:** Wild and captivity monkeys are infested by several parasites species, mainly, *Strongyloides* sp. and *Acanthocephala* sp, which has been identified as the major causes of illness and death. However, *Molineus torulosus* is a pathogenic nematode found in Neotropical New World Primates and causes severe illness in small primates due to severe gastrointestinal injury. In South America, the parasite was described in *Cebus apella* and *C. olivecaeus* from French Guyana and were verified the occurrence in tropical forests. Thus, it is the first report about *M. torulosus* infestation in captivity capuchin monkeys in Brazil.

**Case:** Two capuchin monkeys were presented for necropsy. According to veterinarian the monkeys had about five years old and weighed 0.9 kg and lived in a particular park in urban with 20 to 30 capuchin monkeys group. The veterinarian described that six capuchin monkeys were found dead in two months period. One of the monkeys were found dead and another one had respiratory disturbance, apathy, prostration, cyanotic mucosa, feces with green coloration and death after four days in observation and isolation of the group. Necropsy confirmed emaciation and moderate splenomegaly, great amount of fibrin on the intestine and presence of multifocal 1 to 2 cm nodules in small intestine with numerous parasites mainly initial portion. In the small intestine, were found several free helminthes in the feces. No parasite was attached in the gut wall. The parasites in the nodules were submitted to a standard nematode key identification, confirming the infestation by *M. torulosus*. The parasites were small, slender, pale red, of 4 to 6 mm length. There were no significant macroscopic findings in the other organ systems. The histological examination of nodules sections revealed an intense granulomatous inflammatory response surrounded by proliferating fibrous connective tissue and the central portion contained a mass of nematode parasites and their eggs surrounded by eosinophilic debris. The small intestine revealed the presence of eggs and larvae at the villi, epithelium and crypts necrosis areas, villi atrophy and congestion, mononuclear inflammatory reaction.

**Discussion:** There are no reports of *Molineus torulosus* parasitism in captivity capuchin monkeys in Brazil. The clinical signs described in the present case were unspecific and the parasite identification was a necropsy found. However, the infestation with *M. torulosus* was associated with enteritis and diarrhea. The parasite causes hemorrhagic or ulcerative enteritis, sometimes associated with diverticula of the intestinal wall. Furthermore, the capuchin monkeys death in the present case was assigned with a fibrinous peritonitis and septicemia because a gut wall necrosis caused by *M. torulosus* infestation. Thus, the high density of *M. torulosus* in the small intestine is believed to be responsible for the death of these capuchin monkeys. The present report identifies the nematode *M. torulosus* and associated with capuchin monkey mortality. Thus, the present case also highlights the importance of performing a complete necropsy on monkeys, including thorough examination of the gastrointestinal system, and stresses the value of saving fresh tissues for diagnostic procedures including parasite recovery and identification.

**Keywords:** capuchin monkey, *Cebus apella*, *Molineus torulosus*, enteritis, nematode, parasitic granuloma.

## INTRODUCTION

*Molineus torulosus* is a parasite found in Neotropical New World Primates, like *Cebus* sp., *Aotus* sp. and *Saimiri* sp. from Central and South America [3,6,8]. In South America, the parasite was described in *Cebus apella* and *C. olivecaeus* from French Guyana and were verified the occurrence in tropical forests [3]. This a first report about *Molineus torulosus* infestation in captivity capuchin monkeys in Brazil.

Generally, wild and captivity non-human primates are infested by several parasites species. Amongst, *Strogylodes* sp. and *Acanthocephala* sp. has been identified as the major causes of illness and death [5]. However, the *Molineus* sp. causes severe illness in small primates due to severe gastrointestinal injury, mainly, in the small intestine and pancreas [2]. The current paper describes captivity capuchin monkeys (*Cebus apella*) mortality by *Molineus torulosus* parasitism in midwestern Brazil.

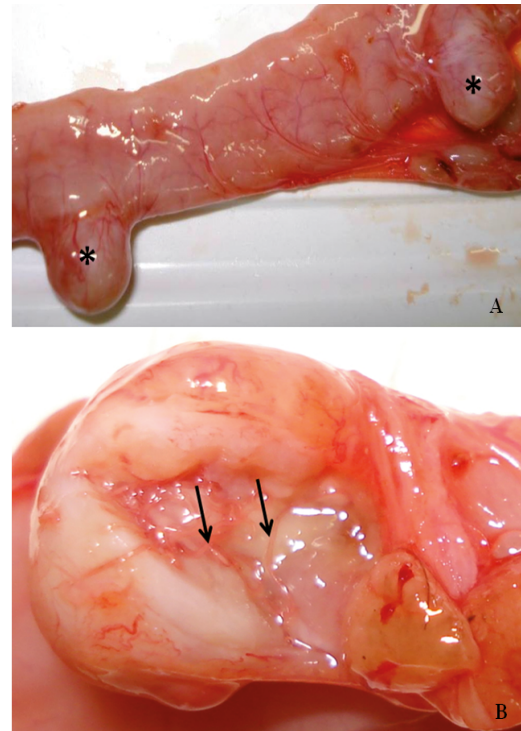
## CASE REPORT

Two captivity *Cebus apella* were submitted to necropsy. According to veterinarian the animals had about five years old and weighed 0.9 kg. The capuchin monkeys lived in a particular park in urban with 20 to 30 capuchin monkeys group. The veterinarian described that six capuchin monkeys were found dead in two months period. One of the monkeys were found dead and another one had respiratory disturbance, apathy, prostration, cyanotic mucosa, feces with green coloration and death after four days in observation and isolation of the group.

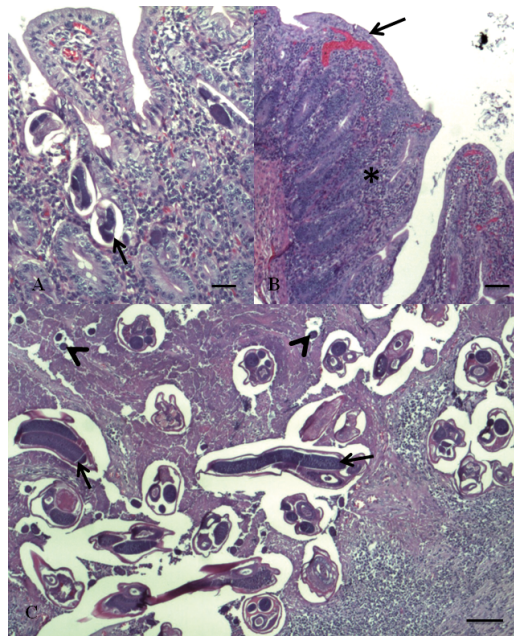
After necropsy, sections of major organs were fixed in 10% neutral buffered formalin, embedded in paraffin, sectioned at 5  $\mu$ m, and stained with Hematoxylin and Eosin (H&E). The parasites found in the gut were preserved in 70% ethanol and fecal samples of large gut were refrigerated. The parasites and feces were submitted to parasitological identification. The fecal samples and adult parasites were processed according to described by Hoffman [4] and standard nematode parasites identification keys were used during examination of the parasites [1,9]. Fluke morphology, size, tissue location, and host in the present case were consistent with an identification key of *Molineus torulosus*.

Necropsy confirmed emaciation and moderate splenomegaly, great amount of fibrin on the intestine and presence of multifocal nodules in small intestine mainly in initial portion (Figure 1A). The nodules were white colored and had a 1 cm in diameter. In the small intestine, were found several free helminthes in the feces. Several parasites were found in the feces of the small intestine (Figure 1B). The parasites were small, slender, pale red, of 4 to 6 mm length. No parasite was attached in the gut wall. There were no significant macroscopic findings in the other organ systems. Macroscopic and histological findings were recorded in a standard examination protocol and documented photographically.

The histological examination of nodules sections revealed an intense granulomatous inflammatory response surrounded by proliferating fibrous connective tissue and the central portion contained a mass of nematode parasites and their eggs surrounded by eosinophilic debris (Figure 2C). The small intestine revealed the presence of eggs and larvae at the villi (Figure 2A), epithelium and crypts necrosis areas, villi atrophy, mononuclear inflammatory reaction and villi congestion (Figure 2B).



**Figure 1.** Small intestine of *Cebus apella*. A) Serosa parasitaries nodules (\*). B) Nodule cut section exhibit nematodes in central portion (arrows).



**Figure 2.** Small intestine of *Cebus apella*. A) *Molineus torulosus* (arrows) and their eggs (arrowheads) at the villi (H&E) [Bar = 30  $\mu$ m]. B) Epithelium necrosis, villi atrophy (arrow), and congestion associated to mononuclear inflammation in small intestine (\*) (H&E) [Bar = 60  $\mu$ m]. C) *M. torulosus* (arrow) and their eggs (arrowhead) surrounding by fibrous connective tissue, granulomatous inflammatory reaction and eosinophilic debris (H&E) [Bar = 30  $\mu$ m].

## DISCUSSION

The clinical signs described in the present case were unspecific and the parasite identification was a necropsy found. However, the infestation with *Molineus torulosus* was associated with enteritis and diarrhea. *M. torulosus* cause hemorrhagic or ulcerative enteritis, sometimes associated with diverticula of the intestinal wall [7,8]. Furthermore, the capuchin monkey death in the present case was assigned with a fibrinous peritonitis and septicemia because a gut wall necrosis caused by *M. torulosus* infestation. So, the high density of *M. torulosus* in the small intestine is believed to be responsible for the death of these capuchin monkeys.

The gross [3,5,8] and histological [8] findings were described previously. Fluke morphology of the parasite was consistent with an identification of *Molineus torulosus*, resembling previous descriptions [2,3,5,8]. There are no published descriptions about *M. torulosus* parasitism in captivity *Cebus apella* in Brazil. *Molineus torulosus* is the only species reported to be a pathogenic in *C. apella* [8]. The nematode infestation causes severe gastrointestinal lesions or

disturbance in others systems because erratic migration of the parasite or cause the death of monkeys [2,6]. The presence of the parasite and their ova occur because the eggs pass by 1-mm reddish brown ulcer that communicated the nodule with the intestinal lumen [6]. Furthermore, these authors reported the presence of the adult *M. torulosus* in pancreatic ducts and multifocal or diffuse chronic pancreatitis in capuchin monkeys.

The present report identifies the nematode *Molineus torulosus* and associated with capuchin monkey mortality. Thus, the present case also highlights the importance of performing a complete necropsy on monkeys, including thorough examination of the gastrointestinal system, and stresses the value of saving fresh tissues for diagnostic procedures including parasite recovery and identification.

**Acknowledgements.** The authors are grateful to Prof. José L. B. Araújo for the support on parasitological exam and parasite identification and to Prof. Igo G. Guimarães for reviewing the manuscript.

**Declaration of interest.** The authors report no conflicts of interest. The authors alone are responsible for the content and writing of the paper.

#### REFERENCES

- 1 **Anderson R.C., Chabaud A.G. & Wilmott S. 2009.** *Keys to the Nematode Parasites of Vertebrates: Archival Volumes*. Cambridge: CAB International, 463p.
- 2 **Brack M., Myers B.J. & Kuntz R.E. 1973.** Pathogenic properties of *Molineus torulosus* in capuchin monkeys, *Cebus apella*. *Laboratory Animal Science*. 23(3): 360-365.
- 3 **Durette-Desset M.C., Fribourg Blanc L.A. & Vuong P.N. 2001.** *Molineus torulosus* (Nematoda, Trichostrongylina, Molineoidea) a parasite of Neotropical primates: new morphological and histological data. *Parasite*. 8(1): 53-60.
- 4 **Hoffman R.P. 1987.** *Diagnóstico de parasitismo veterinário*. Porto Alegre: Sulina, 156p.
- 5 **Kuntz R.E. 1982.** Significant Infections in Primate Parasitology. *Journal of Human Evolution*. 11: 185-194.
- 6 **McClure H.M. & Chandler F.W. 1982.** A survey of pancreatic lesions in nonhuman primates. **Veterinary Pathology**. 19(Suppl 7): 193-209.
- 7 **Müller B. 2007.** Determinants of the diversity of intestinal parasite communities in sympatric New World primates (*Saguinus mystax*, *Saguinus fuscicollis*, *Callicebus cupreus*). 217p. Germany. Doctoral thesis (Doctoral in Veterinary Medicine), University of Veterinary Medicine, Hannover.
- 8 **Toft J.D. 1982.** The pathoparasitology of the alimentary tract and pancreas of nonhuman primates: A review. *Veterinary Pathology*. 19(7): 44-92.
- 9 **Vicente J.J., Rodrigues H.O., Gomes D.C. & Pinto R.M. 1977.** Nematóides do Brasil. Parte V: Nematóides de Mamíferos. *Revista Brasileira de Zoologia*. 14(Supl 1): 1-452.