

# Orthodontic treatment plan changed by 3D images

Iury Oliveira Castro\*, Carlos Estrela\*\*, José Valladares-Neto\*\*\*

## Abstract

**Introduction:** Cone-Beam Computed Tomography (CBCT) was introduced in the 90's and studies have improved its use in dentistry. **Objective:** The aim of this article was to investigate the influence of three-dimensional (3D) images in orthodontic treatment planning. **Methods:** Two clinical situations (bone dehiscence and cervical resorption) were described by 3D images. **Results:** The orthodontic treatment plan was redirected to a simplified mechanics and control of the lesions during orthodontic treatment. **Conclusion:** 3D images are able to increase diagnostic accuracy and redirect orthodontic treatment plan.

**Keywords:** Orthodontic treatment plan. Cone-Beam computed tomography. Cervical resorption. Bone dehiscence.

## INTRODUCTION

Conventional (or medical) computed tomography (CT) was developed in 1972 by the English engineer Hounsfield and the American physicist Comark.<sup>2</sup> It represented great progress, and for this reason, its creators were recognized with the Nobel Prize for Medicine in 1979. Despite the advances, conventional CT has been applied in dentistry with restrictions due to high radiation doses, excessive size of the device, the need for the patient to be in supine position during the

shot and its cost.<sup>2,10,19</sup> Towards the end of the 90's, technological advances led to a new version that met the needs of dental and maxillofacial regions, and became known as Cone-Beam Computed Tomography (CBCT).<sup>4,6,10</sup>

As the name suggests, the CBCT produces radiation in the shape of a cone that rotates around the patient to acquire volumetric data. A specific amount of absorbed X-rays corresponds to a three-dimensional cuboid structure, called voxel—corresponding to the pixel in the

\* Postgraduate Student, School of Dentistry, Federal University of Goiás, Goiás, Brazil.

\*\* Head and Professor of Endodontics, School of Dentistry, Federal University of Goiás, Goiás, Brazil.

\*\*\* Assistant Professor of Orthodontics, School of Dentistry, Federal University of Goiás, Goiás, Brazil.

two-dimensional images. The computer volumetric reconstruction is obtained by using software algorithms to reproduce the three dimensional image (3D) in high resolution.<sup>18</sup> The radiation dose emitted by CBCT depends on the desired field of view, exposure time, kilovoltage and milliamperage, but it has been reported that it corresponds to approximately 20% of a conventional CT and it is equivalent to the complete exposure of periapical radiographs.<sup>17</sup> The differential in the CBCT is also the possibility of shooting in real size in all three planes of space, unlike the two-dimensional X-rays that project the image of the structures in one plane, often distorted and overlapped.<sup>4</sup>

The literature is rich in clinical applications for the CBCT.<sup>13</sup> In orthodontics, it allows for the visualization of impacted teeth,<sup>10,13,18,19</sup> detection of root resorption, ankylosis and dentoalveolar fracture,<sup>7,10</sup> assessment of height and bone volume,<sup>10,13</sup> investigation of temporomandibular joint and upper airway,<sup>4,13,19</sup> accurate determination of bone-tooth discrepancies in non-erupted teeth<sup>10</sup> and diagnosis of pathologies.<sup>13,18</sup>

The aim of this paper was to evaluate the influence of 3D exams in redirecting the orthodontic treatment plan. For this, two clinical situations were described, in which the clinical examination and/or conventional radiographic exams suggested complementation with tomographic images. In both cases, images were acquired by the tomograph i-CAT® (Imaging Sciences International,

Hatfield, USA) whose data were exported to Xoran software version 3.1.62 (Xoran Technologies, Ann Arbor, USA) for 3D reconstruction.

### CASE 1

A 40 year-old male patient sought orthodontic treatment. His main complaint was the poor distribution of spaces in the lower arch for proper rehabilitation with dental implants. His medical history had no significant remarks and dental records showed history of tooth loss (teeth 12, 36 and 37), endodontic treatment (teeth 11, 22 and 46) and the presence of an implant (region of tooth 12). He presented a Class II division 2 left subdivision malocclusion, with a lower midline deviation to the left side, distal migration of the teeth 33, 34 and 35, and mild crowding in the upper and lower arches (Figs 1 and 2).

The initial orthodontic treatment plan aimed to obtain ideal occlusion. However, a depression was observed in the sub-gingival buccal surface of tooth 22 during periodontal probing, suggestive of perforation or cervical root resorption. Since the lesion was not detected radiographically and its extension had not been defined clinically, a CBCT was requested. CT imaging confirmed the presence of a defect (dehiscence of labial cortical bone) and labial cervical root resorption of tooth 22 (Figs 1 and 2). Based on the risk of losing the affected incisor during orthodontic movement and the main complaint of the patient, the decision was shared with the patient and redirected to treatment simplification.

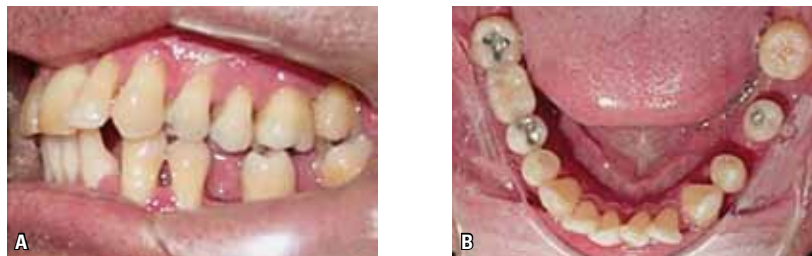


FIGURE 1 - **A)** Left lateral view and **B)** lower occlusal view. Distal migration of teeth 33, 34 and 35 and buccal tipping of the tooth 22. Lower spaces as a result of early loss of permanent teeth.

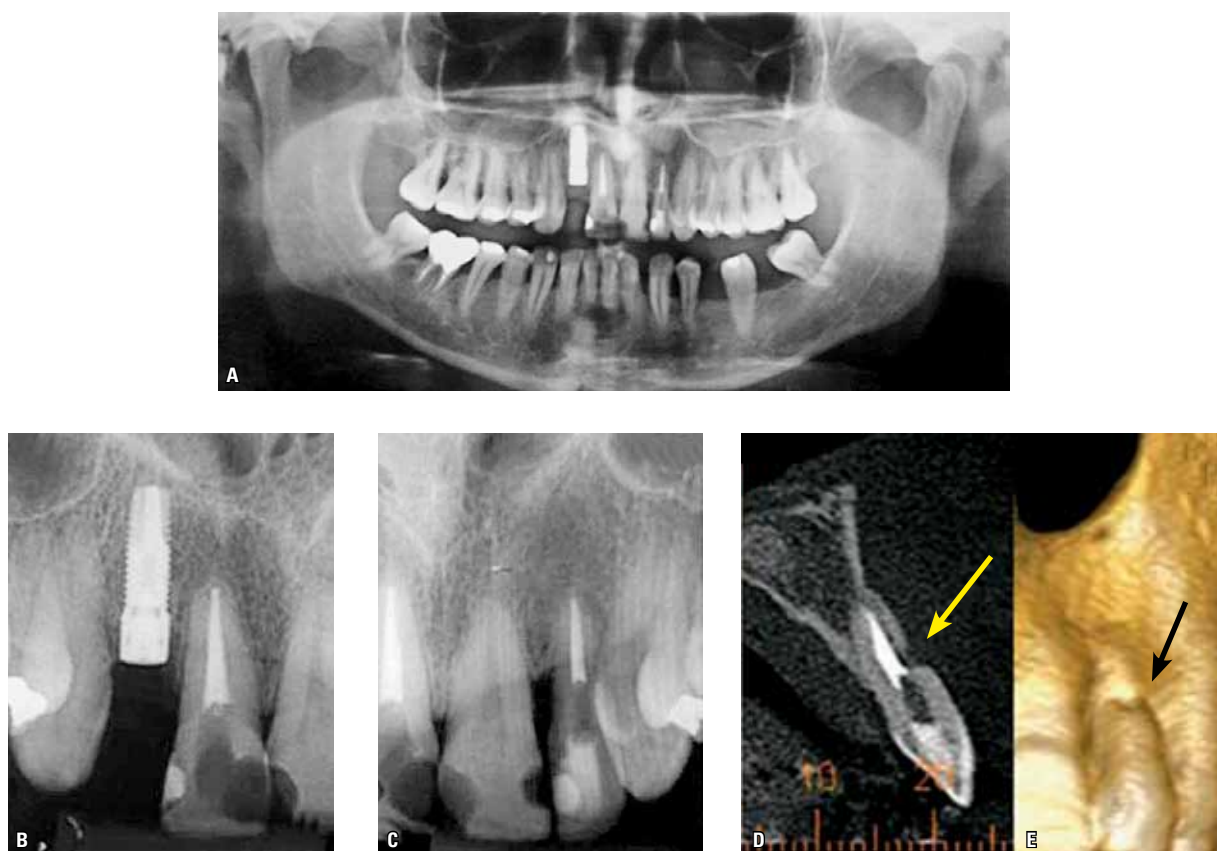


FIGURE 2 - **A)** Endodontic treatment of teeth 11, 22 and 46. Increased periodontal space on tooth 46 and **B)** presence of implant in the region of tooth 12. **C)** Detail of the region of upper anterior teeth. **D)** CBCT of tooth 22. Absence of vestibular cortical bone and root resorption in the middle third of the buccal root of tooth 22 and **E)** 3D reconstruction. Note the bone loss and root resorption in tooth 22.

The fixed appliance was installed only in the lower jaw to preserve the integrity of the tooth affected by resorption and promote the redistribution of adequate space for installation of dental implants with appropriate functional guide.

## CASE 2

A 41 year-old old male patient sought orthodontic treatment after two years of a previous treatment with upper first premolar extractions. He complained of not having completed the treatment adequately. His main complaint was the “spaces between front teeth” (Fig 3). His medical history had no significant remarks. Regarding the dental pattern, he had an Angle Class II malocclusion with

spaces between the upper teeth and lower crowding. Horizontal bone loss was observed on the radiographic survey in the upper anterior region and apical root resorption in teeth 11, 12, 13, 15, 21, 22, 23 and 25 (Fig 3).

Due to doubts about the amount of insertion of the remaining teeth, a CBCT was requested. The 3D images additionally showed extensive bony dehiscence in teeth 13, 16, 23 and 26, undetected by previous clinical examination and conventional radiography (Fig 3). The patient was informed of his dental and periodontal tissue conditions, and consented on the orthodontic treatment focused on solving his complaint. Light and intermittent forces were applied in longer intervals of

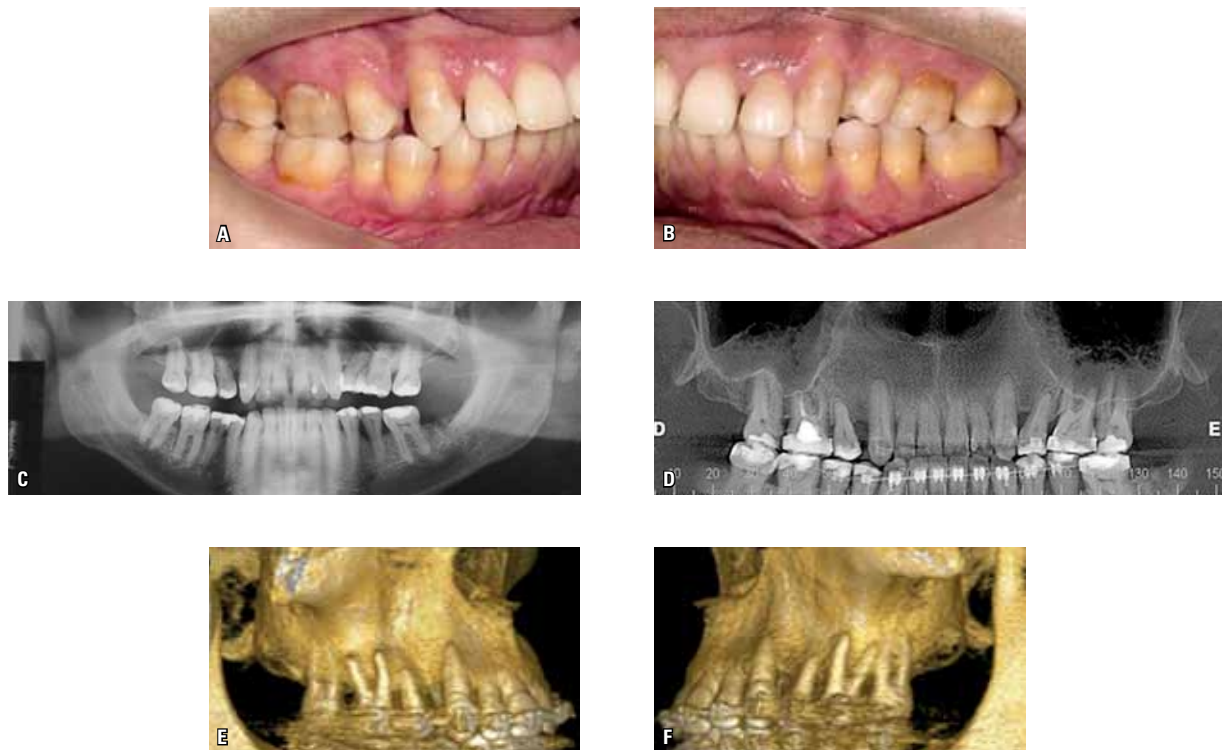


FIGURE 3 - **A, B**) Detail of the region of anterior teeth and diastema between teeth. **C**) Initial panoramic radiography. **D**) CBCT showing uniform horizontal bone loss and root resorption of the elements 11, 12, 13, 15, 21, 22, 23 and 25. **E, F**) CBCT reconstruction (right and left). Note the horizontal alveolar bone loss and dehiscence in buccal roots of the elements 23, 26, 16 and 13.

activation for the control of pre-existing apical root resorption, and expansion and buccal root torque were avoided in view to bone dehiscences.

## DISCUSSION

Diagnostic information is essential for the valid decision of a treatment plan. Accurate images lead to a better treatment plan and enhance more predictable and appropriate results. The CBCT is an emerging technology appropriate for the dental region and maxillofacial structures, which can offer the most relevant clinical information when compared with conventional radiographs.

As the demand for orthodontic treatment in adults has increased dramatically in the last two decades, the need for a more detailed diagnosis

is necessary.<sup>3</sup> The adult patient has features, such as higher prevalence of periodontal disease, tooth loss, endodontically restored teeth, restored teeth and trauma sequelae, coexisting with malocclusion. Orthodontic retreatment cases raise the possibility of iatrogenic injuries, such as external apical root resorption and bone dehiscence.

In cases of resorption due to orthodontic treatment, it is suggested by a clinical study that clastic activity is activated with orthodontic force and paralyzed with its discontinuation.<sup>15</sup> As shown by Giannopoulou et al,<sup>8</sup> tooth movement is also able to induce cervical root resorption. For that reason, the tooth with cervical root resorption was not included in the orthodontic movement in Case 1 and, for Case 2,

a periodical radiographic control<sup>16</sup> and biomechanics for external apical root resorption control were performed. Among the biomechanical measures for protection, the use of longer intervals for appliance activation,<sup>15</sup> the use of light and intermittent forces instead of heavy and continuous<sup>1,5</sup> forces and restricting the intrusive movement were included.<sup>9</sup>

Bone dehiscence and fenestration are potentially detected during surgical procedures. In a recent study,<sup>14</sup> the accuracy and reliability of CBCT in the diagnosis of bony dehiscence and fenestration have been tested and is effective as a non-surgical diagnostic method. Case 2 showed extensive bone dehiscence through 3D images, not detected radiographically. The diagnostic information led to caution in the expansion movement and root torque, during orthodontic treatment, to prevent dehiscence aggravation.

The changes in treatment plan for the reported cases resulted from information of 3D images. Clinical examination and conventional

radiography were unable to diagnose or determine the extent of the injury, but originated issues that justified the indication of CT scan.

Criteria for the request of CBCT are still being established. Guidelines from the British Orthodontic Society<sup>12</sup> and the European Academy of Dental and Maxillofacial Radiology<sup>11</sup> recommend that the CBCT should be used cautiously, without repetition or routinely, but as a complementary tool for conventional exams.

## CONCLUSION

The CBCT is a technological advance in obtaining dental and maxillofacial imaging. Three-dimensional imaging can identify lesions masked by two-dimensional limitations of conventional exams and can redirect the orthodontic treatment plan. However, the routine use of CBCT should still not be recommended, but it should be used as a complementary tool when questions arise after clinical examination and/or conventional radiography.

## REFERENCES

1. Ballard DJ, Jones AS, Petocz P, Darendeliler MA. Physical properties of root cementum: part 11. Continuous vs intermittent controlled orthodontic forces on root resorption. A microcomputed-tomography study. *Am J Orthod Dentofacial Orthop.* 2009 Jul;136(1):1-9.
2. Bueno MR, Estrela C, Azevedo BC, Brugnera Júnior A, Azevedo JR. Tomografia computadorizada cone beam: revolução na Odontologia. *Rev Assoc Paul Cir Dent.* 2007 set-out;61(5):354-63.
3. Buttke TM, Proffit WR. Referring adult patients for orthodontic treatment. *J Am Dent Assoc.* 1999 Jan;130(1):73-9.
4. Cattaneo PM, Melsen B. The use of cone-beam computed tomography in an orthodontic department in between research and daily clinic. *World J Orthod.* 2008 Oct;9(3):269-82.
5. Chan E, Darendeliler MA. Physical properties of root cementum: Part 5. Volumetric analysis of root resorption craters after application of light and heavy orthodontic forces. *Am J Orthod Dentofacial Orthop.* 2005 Feb;127(2):186-95.
6. Estrela C, Bueno MR, Azevedo BC, Azevedo JR, Pécora JD. A new periapical index based on cone beam computed tomography. *J Endod.* 2008 Nov;34(11):1325-31.
7. Estrela C, Bueno MR, Alencar AH, Mattar R, Valladares-Neto J, Azevedo BC, et al. Method to evaluate inflammatory root resorption by using cone beam computed tomography. *J Endod.* 2009 Nov;35(11):1491-7.
8. Giannopoulou C, Dudic A, Montet X, Kiliaridis S, Mombelli A. Periodontal parameters and cervical root resorption during orthodontic tooth movement. *J Clin Periodontol.* 2008 Jun;35(6):501-6.
9. Harris DA, Jones AS, Darendeliler MA. Physical properties of root cementum: part 8. Volumetric analysis of root resorption craters after application of controlled intrusive light and heavy orthodontic forces: a microcomputed tomography scan study. *Am J Orthod Dentofacial Orthop.* 2006 Nov;130(5):639-47.
10. Holdberg C, Steinhäuser S, Geis P, Rudzki-Janson I. Cone-beam computed tomography in orthodontics: benefits and limitations. *J Orofac Orthop.* 2005 Nov;66(6):434-44.
11. Horner K, Islam L, Flygare L, Tsiklakis K, Whaites E. Basic principles for use of dental cone beam computed tomography: consensus guidelines of the European Academy of Dental and Maxillofacial Radiology. *Dentomaxillofacial Radiology.* 2009 May;38(4):187-95.
12. Issacson KG, Thom AR, Horner K, Whaites E. Orthodontic radiographs guidelines. 3<sup>rd</sup> ed. London: British Orthodontic Society; 2008.
13. Kau CH, Richmond S, Palomo JM, Hans MG. Three-dimensional cone beam computerized tomography in orthodontics. *J Orthod.* 2005 Dec;32(4):282-93.
14. Leung CC, Palomo L, Griffith R, Hans MG. Accuracy and reliability of cone-beam computed tomography for measuring alveolar bone height and detecting bony dehiscences and fenestrations. *Am J Orthod Dentofacial Orthop.* 2010 Apr;137(4 Suppl):109-19.
15. Levander E, Malmgren O, Eliasson S. Evaluation of root resorption in relation to two orthodontic treatment regimes: a clinical experimental study. *Eur J Orthod.* 1994 Jun;16(3):223-8.
16. Levander E, Bajka R, Malmgren O. Early radiographic diagnosis of apical root resorption during orthodontic treatment: a study of maxillary incisors. *Eur J Orthod.* 1998 Feb;20(1):57-63.
17. Mah JK, Danforth RA, Bummann A, Hatcher D. Radiation absorbed in maxillofacial imaging with a new dental computed tomography device. *Oral Surg Oral Med Oral Pathol Oral Radiol Endod.* 2003 Oct;96(4):508-13.
18. Merrett SJ, Drage NA, Durning P. Cone beam computed tomography: a useful tool in orthodontic diagnosis and treatment planning. *J Orthod.* 2009 Sep;36(3):202-10.
19. Nakajima A, Sameshima GT, Arai Y, Homme Y, Shimizu N, Dougherty H Sr. Two- and three-dimensional orthodontic imaging using limited cone beam-computed tomography. *Angle Orthod.* 2005 Nov;75(6):895-903.

Submitted: March 2010  
Revised and accepted: July 2010

**Contact address**

Iury Oliveira Castro  
Al. Cel. Eugênio Jardim, n. 312 Setor Marista  
CEP: 74.175-100 - Goiânia / GO  
E-mail: iurygo@hotmail.com